



FROM THE DIRECTOR

H. Leon Thacker, DVM, PhD

Ahh, the pleasant days and nights of Indiana fall weather. This is one of the somewhat hidden benefits of living in our State; this is a wonderful time of year. Our concern and offers of assistance go out to our countrymen in the states to our south who were so devastated by the storms, the losses in the affected areas are felt by us all. Fall brings a new set of challenges and adjustments with the start of the new school year and the seasonal change of animal and people disease spectra. One of the topics that is receiving a lot of press now is the newly recognized canine influenza that is an H3N8 type. We have had two

suspicious cases of this condition presented to our Indiana laboratories; however, the specimens as received were not confirmed as definitive for this condition.

Later this fall, we will be testing about 1,000 hunter-killed deer for Chronic Wasting Disease by the immunohistochemistry method. This testing will be in cooperation with the Indiana DNR as surveillance for the presence of CWD in our state. Testing has been performed in the fall of each of the past four years for CWD in our deer; so far none have been found. ADDL is also participating in the national surveillance program for Scrapie of sheep and goats, the IHC testing procedure is essentially identical to that of CWD testing. We're running a few hundred Scrapie tests/week on samples collected by state and federal veterinarians, primarily in slaughter facilities. Our bacteriology laboratory is and has been very busy also in performing the testing for the nationally supported state surveillance program for Johne's disease in Indiana cattle. All of these processes involve intricate sample manipulation and testing procedures.

We recently had three veterinary scientists from Morocco in our laboratory participating in a USDA sponsored learning program that involved specially prepared short courses in bacteriology, immunohistochemistry, immunology, epidemiology and molecular diagnostics taught by members of the ADDL faculty. The program prepared for the scientists also involved trips to the National Veterinary Services Laboratory in Ames, Iowa and the National Foreign Animal Disease Laboratory on Long Island, New York. The program was judged to be a very successful one and very beneficial to our fellow diagnostic scientists from Morocco. Special thanks to our faculty for providing the instruction to them.

Hope you enjoy our fall weather and again invite you to let us know if there are services that we should be providing to accommodate your diagnostic needs. We are here to serve you.

Final Diagnosis Renal Dysplasia in a Lhasa Apso.....	1
What do we know about PCV2?.....	3
Listeriosis in Ruminants and Human Risk.....	4
Acute gastric dilatation-volvulus in dogs.....	5
ADDL Schedule.....	6
Canine Osteosarcoma.....	6
ADDL News.....	7
Virology/Serology Update.....	8

FINAL DIAGNOSIS: Renal Dysplasia in a Lhasa Apso

In each issue, we will feature a case submitted to ADDL that we hope will be of interest to you.

History: A 3.5 year old neutered male Lhasa Apso with a one-week history of lethargy and anorexia was submitted for necropsy to the Purdue Animal Disease Diagnostic Laboratory. The

serum chemistry revealed increase in BUN (142 µg/dl), creatinine (7.8 µg/dl), phosphorus (10.2 µg/dl) and normal calcium (10.2 µg/dl). Ultrasound examination revealed small kidneys. Upon poor prognosis, the animal was euthanized and submitted for necropsy.

Gross findings: Both kidneys were misshapen, shrunken, modular with diffusely pitted surfaces. The renal weight was 0.18% of the body weight. Both external parathyroid glands were red, smooth and enlarged. The mandibles of this dog were flexible and could be easily deviated laterally in either direction ("rubber jaw"). The ribs and calvarium were thin, brittle and prone to fracture upon applying pressure.

Histopathologic findings: The cortex and medulla in both kidneys were variably shrunken and often replaced by linear bands of fibrosis that surrounds and replaces tubules, glomeruli, and vessels and extends into the medullary interstitium. Rare glomeruli are reduced in size and contain closely packed hyperchromatic nuclei (fetal or immature glomeruli). Multifocally, the collecting tubules in the medulla were dilated, lined by epithelium with a scant amount of cytoplasm and hyperchromatic nuclei (primitive or immature tubules) and surrounded by loose and poorly differentiated stroma (mesenchyme). In addition, rare tubules in the medulla had adenomatous differentiation (resembling acini) of the epithelium. Mineralization, necrosis and regeneration of the tubular epithelium were present. The

parathyroid glands were diffusely hyperplastic. Most of the mature bone in the mandibles and sinuses was fragmented and replaced by sheets of fibrous connective tissue admixed with numerous scattered osteoclasts. Occasionally, osteoid lined by osteoblasts was seen (new bone formation). The morphologic diagnoses were renal dysplasia, parathyroid hyperplasia and fibrous osteodystrophy of the mandible.


Discussion: Renal dysplasia is defined as disorganized development of renal parenchyma due to abnormal differentiation, i.e., presence of inappropriate structures for specific developmental stage of the animal or development of anomalous structures. Abnormal metanephric differentiation and nephrogenesis is due to failure or incomplete interaction between the ureteric bud and metanephric blastema. In dogs, the lesions associated with renal dysplasia include fetal/immature glomeruli and/or tubules, adenomatoid tubular epithelium, persistent mesenchyme and metanephric ducts. A definitive diagnosis of renal dysplasia in this dog was made based on the presence of fetal glomeruli, primitive tubules and persistent mesenchyme. This condition is reported to have hereditary predisposition in Golden retrievers, Shih Tzus, Boxers, Finnish harriers, Dutch Kooiker, Cocker spaniels and Lhasa Apsos. Unfortunately, in this dog, no familial history was submitted.

Fibrous osteodystrophy is due to hyperparathyroidism secondary to renal dysfunction. Persistent hypocalcemia (due to kidney dysfunction) causes continued stimulation of parathyroid hormone resulting in parathyroid chief cell hyperplasia (renal secondary hyperparathyroidism). Parathyroid hormone acts primarily on bone and kidney by stimulating bone resorption and calcitriol production, respectively. Continuous bone resorption by osteoclasts results in characteristic marked softening of bones and replacement with fibrous connective tissue (fibrous osteodystrophy).

The prognosis in animals diagnosed with renal dysplasia is poor. Affected dogs can be maintained for some duration on supportive treatments. Careful breeding by avoiding carrier animals should be of help in limiting this disease.

-by Dr. Vimala Vemireddi, ADDL Graduate Student





What do we know about PCV2?

Porcine circovirus type 2 (PCV2) is considered by most to be the etiologic agent of postweaning multisystemic wasting syndrome (PMWS), but it is also found in association with numerous other conditions. These conditions include porcine dermatitis and nephropathy syndrome (PDNS), porcine respiratory disease complex (PRDC), congenital tremors (CT) type All, reproductive failure and enteritis. Although PCV2 has been determined to be associated with many of these conditions, there is still no scientifically sound proof that it is the causal agent. Much of the role played by PCV2 in today's swine industry is still a mystery. We do know that the incidence of PCV2 associated conditions continue to rise in the U.S. PCV2 associated diseases have increased from 37 cases in 1997 to 1,116 cases in 2002 at the Iowa State University Veterinary Diagnostic Laboratory (ISU-VDL).

PCV1 was detected in swine populations but, to date, has not been associated with any clinical disease. Although PCV1 and PCV2 are antigenically similar, they can be differentiated by molecular tests. Like PCV1, PCV2 is prevalent in virtually every herd. Much research is focused on trying to determine why the prevalence of PCV2-associated disease is relatively low while the prevalence of PCV2 is so high. There may be numerous contributing factors in the development of the various disease conditions.

PMWS

PMWS was first recognized in high health Canadian herds in 1991 and is seen in almost every country now. Although morbidity is usually 100%, mortality can approach 5-50%. This syndrome most often affects pigs 4-12 weeks of age and is diagnosed by meeting all of the following three criteria:

1. Clinical signs and gross lesions – wasting, slowed growth, enlargement of inguinal lymph nodes and frequently dyspnea, noncollapsed and mottled lungs and occasionally jaundice
2. Characteristic histological lesions – lymphocyte depletion in secondary lymphoid tissues, granulomatous inflammation in numerous organs, interstitial pneumonia and often basophilic cytoplasmic inclusion bodies in macrophages
3. Demonstration of PCV2 within lymphoid tissue lesions by IHC, PCR or *in situ*

hybridization; virus isolation is also offered by some laboratories.

There has been much uncertainty in the relationship between PCV2 and PMWS but Bolin et al demonstrated that Koch's postulates could be fulfilled by inoculating cesarean-derived, colostrum-deprived (CDCD) pigs with PCV2 and producing clinical signs of PMWS. Similar work has been performed using an infectious genomic clone of PCV2 in specific pathogen free (SPF) pigs to produce the gross and microscopic lymphoid lesions of PMWS. Although PCV2 has been shown to induce PMWS lesions in CDCD and SPF pigs, the presence of additional factors are required.

It has been suggested that immune stimulation may play an integral role in the development of PMWS in PCV2 infected pigs. This may be a result of any type of management or environmental stress, coinfection with another pathogen or administration of vaccines and adjuvants. Coinfection with porcine parvovirus (PPV) has shown to potentiate the replication and tissue distribution of PCV2 and increase the severity of clinical signs and lesions of PMWS. Although several farms have implemented PPV vaccination programs for growing pigs to try to control PMWS, research has shown that vaccination for PPV does not increase or decrease the severity or incidence of PMWS in dually infected pigs. Dual vaccination of PCV2 infected pigs for *Mycoplasma hyopneumoniae* and *Actinobacillus pleuropneumoniae* has experimentally induced a longer viremia, wider tissue distribution of PCV2 and increased severity and incidence of lymphoid depletion as compared to nonvaccinated pigs. Recent work has demonstrated that oil-in-water adjuvants may contribute to PCV2 induced disease more than other types of adjuvants.

There is no proven treatment or prevention for PMS, but administration of corticosteroids appears to be beneficial in an acute outbreak to reduce the severity of the disease and death loss. This observation may suggest that the syndrome is an immune-mediated disease.

PDNS

PDNS was first described in 1993 in the United Kingdom, but presently has a worldwide distribution. Although PCV2 is often found in cases of PDNS, the current diagnostic criteria for PDNS does not include the detection of PCV2, but does include these two criteria:

1. Necrotizing skin lesions (mainly on rear legs and perineal region) and/or swollen and pale kidneys with generalized cortical petechiae.
2. Systemic necrotizing vasculitis and necrotizing and fibrinous glomerulonephritis

Currently, PDNS is considered to be a type III hypersensitivity reaction, although the antigen associated with this immune-complex disease is not definitively known.

PRDC

PCV2 associated pneumonia is the most common presentation of PCV2 associated disease in cases submitted to ISU-VDL. PCV2 is most often associated with lung lesions in pigs coinfecting with PRRSV, SIV or *Mycoplasma hyopneumoniae*; however, there have been uncomplicated PCV2 pneumonia cases reported in western Canada. PCV2 is determined to be associated with PRDC when PCV2 antigen is associated with characteristic lung lesions. These lesions include necrotizing and ulcerative bronchiolitis, granulomatous inflammation in the alveolar septa and mixed inflammation and fibroplasias in the lamina propria and peribronchiolar areas. It is often difficult to differentiate between cases of PMWS and PCV2 associated pneumonia.

PRRSV infection increases PCV2 replication in experimentally dually inoculated pigs and synergism between these two viruses is also commonly observed in the field. Like PPV, PRRSV and PCV2 all replicate in macrophages and can produce immune cell dysfunction. This may be an important factor in the enhanced replication of PCV2 following PPV or PRRSV infection.

Although *Mycoplasma hyopneumoniae* infects different target cells, PCV2 and *Mycoplasma hyopneumoniae* coinfecting pigs show more severe clinical respiratory disease and lung lesions, poorer growth performance, longer PCV2 viremia and greater amounts of PCV2 antigen in serum, lymphoid and lung tissues than pigs infected with only one pathogen. The peribronchial lymphoid hyperplasia induced by *Mycoplasma hyopneumoniae* seems to provide an important site for PCV2 replication in a lung.

Congenital tremors type All

Currently, the association between PCV2 and CT type All is controversial. A study conducted at Purdue demonstrated by PCR, IHC and *in situ* hybridization that PCV2 was present in CNS and liver tissues from both CT pigs and clinically normal pigs; however, there were more PCV2 infected cells in the CNS of CT pigs than normal pigs. Another study conducted in Europe, however, did not demonstrate an association between PCV2 and CT type All.

Reproductive failure

Although less common than some other PCV2 associated conditions, PCV2 has been associated with reproductive failure, particularly late-term abortions and increased numbers of

mummified fetuses, stillborns and weak pigs. The phenomenon of "stairstep" mummies has been described in which all the fetuses appear to have died during different stages of gestation. The fetuses may have some cardiac hypertrophy and hepatic congestion, but there are not many specific gross lesions observed. There are some characteristic fetal histological lesions, which include severe myocarditis, cardiomyocyte loss, fibrosis and intranuclear inclusion bodies in cardiomyocytes, as well as passive hepatic congestion. PCV2 can be detected by IHC in the myocardial lesions.

Although it is not always certain how PCV2 is transmitted, it has been proven to be shed in semen of infected boars. It is shed sporadically in semen for at least 47 days post-inoculation.

PCV2 obviously plays a diverse role in the swine industry and the incidence of PCV2 associated disease is on the rise throughout the world. There have been no successful prevention and control programs for PCV2 infection. It is known that PCV2 is present on clinically normal farms as well as farms with reported PCV2 associated disease, but the seroprofile of both types of farms is the same. Currently, control of PCV2 associated disease, particularly PMWS and PCV2 associated pneumonia, is based on implementing management practices that minimize stress, eliminating or minimizing the effect of coinfections and eliminating potential triggering factors that induce immune stimulation.

Many European practitioners have attempted serotherapy with varying results, but this technique carries many inherent risks. There has been some promising research concerning the development of a vaccine for PCV2 using a chimeric infectious DNA clone of PCV2 and PCV1. In this study, the nonpathogenic PCV1 genome backbone induced a specific antibody response to the pathogenic PCV2 capsid antigen that was used to make the clone. Much more work must be performed with this clone to determine its potential usefulness as a commercial vaccine.

Until more of the pathogenesis of PCV2 infection is revealed, it will be difficult to control or eliminate this pathogen from swine herds. Efforts must be focused on managing the disease conditions as effectively as possible. PCV2 is currently a significant research topic around the world and, hopefully, these research efforts will help to unravel much of the mystery surrounding this somewhat elusive pathogen.

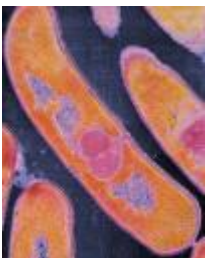-by Dr. Amy Carroll, Class of 2004

-edited by Dr. Roman Pogranichniy, Head of Virology/Serology

References:

1. Bolin WR, WC Stoffregen, GPS Nayar, AL Hamel: 2001. Postweaning multisystemic wasting syndrome induced after experimental inoculation of cesarean-derived, colostrum-deprived piglets with type 2 porcine circovirus. *J Vet Diag Investi* 13: 185-194.
2. Halbur PG: 2001. PMWS: Improved models and recent findings of clinical significance. In *Proc ISU Swine Disease Conference for Swine Practitioners*. 162-166.
3. Halbur PG et al: 2003. PCV2-Associated diseases: Research and diagnostic update. In *Proc. ISU Swine Disease Conference for Swine Practitioners*. 152-160.
4. Halbur PG, T Opriessnig, S Yu, E Thacker: 2002. PMWS: Laboratory experiences. In *Proc ISU Swine Disease Conference for Swine Practitioners*. 76-82
5. Larochelle R, A Bielanski, P Muller, R Magar: 2000. Evidence of shedding of porcine circovirus type 2 (PCV2) in boar semen following experimental infection. In *Proc 16th IPVS, Melbourne, Australia*
6. Pogranichniy RM, KJ Yoon: 2003. New research perspectives on PMWS and its pathogenesis. In *Proc ISU Swine Disease Conference for Swine Practitioners*. 146-151.
7. Ragsdale JM and N Takacs: 2004. Case Studies: Abortions associated with porcine circovirus type 2 in swine. *Swine Practitioner*. Jan, pp 10-11.
8. Segales J and D Marianl: 2003. Diagnosis, prevention and control of PCV2-associated diseases. In *Proc AASV*: 371-376.
9. Stevenson GS et al: 2001. Tissue distribution and genetic typing of porcine circoviruses in pigs with naturally occurring congenital tremors. *J Vet Diag Investi ad*: 57-62.
10. West KH et al: 1999. Myocarditis and abortion associated with intrauterine infection of sows with porcine circovirus 2. *J Vet Diag Investi* 11:530-532.

Listeriosis in Ruminants and Human Risk



Listeriosis, also called Circling Disease or Silage Sickness, is a disease of worldwide occurrence that can affect all ruminants as well as other animal species and humans. It is, therefore, of zoonotic importance. The causative

agent is usually *Listeria monocytogenes*; however ruminants, mainly sheep, also get listeriosis from *Listeria ivanovii* infection.

L. monocytogenes is a ubiquitous, facultative pathogen that is a small, gram-positive, non spore-forming, catalase-positive, facultative anaerobic, motile rod sometimes arranged in short chains. Flagella are produced at room temperatures, but not at 37°C. It can grow in refrigeration temperatures (4°C – also known as cold enrichment) which is why this bacterium can cause severe food-borne infections. Sources of *L. monocytogenes* include soil, mammalian gastrointestinal tract, vegetation and silage.

Listeriosis affects all ages and sexes, but animals less than three years of age are more commonly prone to clinical disease than older animals. The bacterial disease is seen clinically in animals as one of four forms and is more common during the winter or spring months. Adult animals usually get the encephalitis form, while neonates often get the septicemic or visceral form of the disease. Cattle and sheep can also get the abortion form of the disease if there is an intra-uterine infection of the fetus. The fourth form of the disease is ophthalmitis associated with bacterial contamination of the cornea from the feed source. Some lactating ruminants may also have clinical mastitis associated with listeriosis.

The septicemic/visceral form in young animals is due to ingestion of the bacterium and primarily affects the gastrointestinal tract. Bacteria are usually found in the intestinal epithelial cells and specialized epithelial cells covering the Peyer's patches. Infection may be inapparent or may progress to bacteremia resulting in fatal septicemia.

Abortion is caused by placentitis resulting in fetal death and abortion. Some infections by *Listeria sp.* may result in fetal infection leading to stillbirths, neonatal death, or possible viable carriers of the bacteria. Listerial abortion rarely occurs with the encephalitis form of the disease.

The ophthalmic form is often associated with silage feeding and corneal contamination by the bacterium while eating. Ocular involvement may also consist of exposure keratitis if the animal has the encephalitis form with CN VII dysfunction resulting in inability of the animal to blink properly.

Mastitis caused by *L. monocytogenes* is rare but may occur. *L. monocytogenes* does not readily invade the udder. If mastitis occurs, the animal may have prolonged shedding of the bacteria in the milk.

Adult ruminants may also have the visceral form of the infection, but not have clinical disease. The bacterium is generally in the distal intestinal tract and most cases are too mild to be recognized clinically. Animals may commonly be asymptomatic intestinal carriers and shed the organism in significant numbers.

Infection by *L. monocytogenes* has been reported to be increasing in incidence and may be as high as 52% in farm animals, but overt clinical disease is considered to be rare. The disease is diagnosed clinically by the history and presenting signs with a failure of response to thiamine therapy. The most common treatment is oxytetracycline or penicillin G. Therapy works best in animals treated early in the disease process. Sheep and goats usually have an acute form of listeriosis and death occurs in 4-48 hours. Recovery is rare. Cattle, on the contrary, have a more chronic disease with survival for 4-14 days and potential spontaneous recovery with lasting brain damage.

A definitive diagnosis can only be made postmortem by histopathology of the pontomedullary region of the brainstem and by bacterial culture. Usually there are no gross lesions seen in the brain at necropsy. The characteristic microscopic lesions include multifocal asymmetrical microabscesses and mononuclear cell meningoencephalitis (thus, the name *L. monocytogenes*) in the brainstem, anterior spinal cord and, occasionally, cerebellum. Peroxidase-antiperoxidase test, a more accurate diagnostic tool than histopathology, is used to detect degraded bacterial proteins as well as intact bacteria in formalin-fixed tissue.

L. monocytogenes is transmitted from animal to animal through fecal oral routes, usually via manure contamination of the pasture or silage with the microorganism. Animal to human transmission is either directly through contact with infected animals or indirectly via milk, cheese, meat, eggs, or vegetables. The bacterium is inactivated with pasteurization; however, contamination of the pasteurized product with raw product has been reported as a source of infection.

Listeriosis in humans is seen primarily in pregnant women, newborns, elderly, and immunosuppressed (e.g. transplant recipients or AIDS patients). It has been reported that as many as 5-10% of humans may be asymptomatic carriers, harboring *Listeria* sp. in their feces or vagina. Disease in adult humans is commonly of the encephalitic or septicemic/visceral form.

Prevention is the key to listeriosis. In the livestock industry, feeding of spoiled silage and other rotten vegetation should be avoided and any sick animals should be isolated from the healthy animals. Good hygiene and sanitation on the farm is also important.

Whenever possible, people at risk for listeriosis (see above) should avoid the consumption of those foods most frequently linked to listeriosis. Those at risk also need to adhere strictly to the food label directions for storage and "use by" information. It is virtually impossible to provide *Listeria*-free food products because *L. monocytogenes* infects many animal species with many infections being inapparent, and because the bacterium can survive and grow at refrigeration temperature levels.

Other means of prevention include thoroughly washing raw vegetables, thoroughly cooking raw meats, proper hygiene during food preparation, and consuming only pasteurized dairy products. Humans at risk should also avoid contact with animals that have aborted as well as with aborted materials (placenta and fetuses) on the farm.

Finally, livestock and crop producers can help control the spread of *L. monocytogenes* by avoiding the use of untreated manure on vegetable crops.

-by Andrea Starkey, Class of 2005

-edited by Dr. Ingeborg Langohr, ADDL

References

1. Arumugaswamy R and LF Gibson: 1999. *Listeria* in Zoo Animals and Rivers. Australian Veterinary Journal. 77(12): 819-820
2. Cooper, J and RD Walker: 1998. Microbial Food Borne Pathogens: Listeriosis. Veterinary Clinics of North America: Food Animal Practice. 14(1): 113-125.
3. George LW: 2002. Listeriosis. In Smith, Bradford P. large Animal Internal Medicine. 3rd edition, Mosby, Philadelphia, :A 946-949.
4. Finley MR and SR Dennis: 1999. Listeriosis (Circling Disease, Silage Sickness). In Howard & Smith Current Veterinary Therapy 4: Food Animal Practice. Saunders. Philadelphia, PA 396-400.
5. Rebhun, William C: 1995. Listeriosis. In Diseases of Dairy Cattle. Lippincott Williams & Wilkins. Philadelphia, PA 121: 410-413.
6. Ryser ET and EH Marth: 1991. Listeriosis in Animals. *Listeria*, Listeriosis, & Food Safety. Marcel Dekker. New York, NY 33-43.
7. Todar K: 2003. *Listeria monocytogenes* and Listeriosis. Todar's Online Textbook of Bacteriology. University of Wisconsin-Madison,

Department of Bacteriology.

<http://textbookofbacteriology.net/Listeria.html>

8. Whitlock RH: 1999. Brain Stem Diseases of Cattle: Listeriosis. Howard & Smith Current Veterinary Therapy 4: Food Animal Practice. Saunders. Philadelphia, PA. 663-665.

9. Working Group on Zoonoses. Zoonotic Pathogens: Health Risks from Listeria. Vederal Veterinary Office Magazine. June 2002: 14-15.

10. Washington State Department of Health. Listeriosis. October 2002: 1-5.

new bone at the long bone metaphyses may be to blame. They are locally invasive and highly metastatic which makes them particularly hard to manage.

Canine OSA occurs most often in dogs 7-9 years of age, but it has been reported in young (1-2 year old) dogs as well. Large breed dogs are at a much higher risk of developing OSAs (up to 150 times greater risk). A slight predilection for males has been demonstrated, but neutered animals of either sex are twice as likely to develop OSAs as intact animals.

Osteosarcomas can develop in many sites both skeletal and extrasketal; however, extrasketal OSAs only comprise a very small percentage of all canine osteosarcomas. Of the skeletal OSAs, most (approximately 75%) are appendicular. (Therefore, the rest of this article will deal specifically with OSA of this location.) The most common locations for these appendicular osteosarcomas are the distal radius or proximal humerus followed by the proximal and distal femur and tibia. The metaphyseal region is affected most often and the tumor rarely crosses the joint.


Highly aggressive and metastatic in nature, over 90% of all clinically significant OSAs have already micrometastasized by the time of diagnosis. Most metastasis happens via menatogenous spread to the lungs and other bones, but lymph node metastases have been reported.

The typical presentation of canine OSA is lameness of the affected limb with or without a noticeable swelling or mass at the tumor site. The lameness is either due to periosteal inflammation, microfractures, or pathologic fractures. If swelling is present, it is likely due to extension of the tumor into the surrounding soft tissues.


Diagnosis of canine OSA is made based on the clinical presentation described above, a complete orthopedic and neurologic examination (to rule out other causes of lameness), physical examination, regional radiographs and bone biopsy. Radiographic signs include loss of cortical bone, periosteal proliferation, palisading cortical bone, Codman's triangle, loss of fine trabecular pattern in metaphyseal bone, and metaphyseal collapse with a pathologic fracture. Although these changes are distinct, they are not pathognomonic for OSA. Other conditions such as fibrosarcoma (FSA), chondrosarcoma (CSA), and fungal osteomyelitis may be indistinguishable radiographically. This is why a bone biopsy is needed to help obtain an accurate diagnosis.

Purdue ADDL and Heeke ADDL will be closed on the following University holidays in 2005-2006.

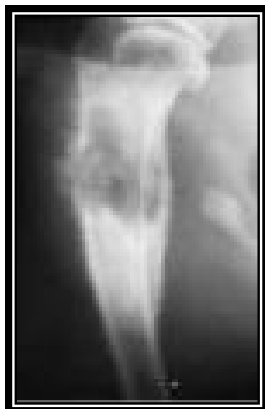Thanksgiving.....Nov 24-25
Christmas.....Dec 23,26
New Year.....Dec 30, Jan 2,'06
Martin Luther KingJan 16,'06



Purdue Animal Disease Diagnostic Laboratory
West Lafayette, IN



Heeke Animal Disease Diagnostic Laboratory
Dubois County, IN



Canine Osteosarcoma

Osteosarcoma (OSA) is the most common primary bone tumor in dogs and cats. Approximately 80-85% of all canine skeletal tumors are diagnosed

as osteosarcomas. Although the exact etiology is unknown, there has been some evidence that derangement of bone growth or differentiation of

Bone biopsies of OSAs can be performed with open or closed techniques. Whichever technique is used, the sample should only include one cortex to maintain as much strength as possible at the biopsy site. Multiple samples should be taken from both the center and the margins of the lesions for a more accurate diagnosis.

Histologically, OSAs consist of malignant mesenchymal cells that appear enlarged and polygonal to spinyloid in shape which produce an osteoid matrix. This osteoid matrix is a distinguishing feature of OSAs. Nonosteogenic bone tumors (FSA, CSA) do not produce this matrix. Subclasses of osteosarcomas are determined based on the characterization of the cells as well as the type and amount of matrix present. Subclasses include osteoblastic, chondroblastic, fibroblastic, poorly differentiated, and telangiectatic osteosarcomas; however, there is no evidence of different biological behavior between the subclasses.

Once a diagnosis has been made, a full evaluation for metastases must be done. Right and left lateral thoracic views must both be done in addition to the ventrodorsal so that all lung fields can be accurately evaluated. Only 10-15% of cases will have detectable metastases at the time of diagnosis in spite of the 90% micrometastatic rate by the same time. To evaluate for bone involvement elsewhere, nuclear scintigraphy or full skeleton radiographs can be performed.

Treatment of canine OSA has one of two goals: palliation of pain and lameness or curative intent. Palliation of the pain is done in cases where metastasis is already evident or to comply with the owner's wishes. It includes the use of analgesics, radiation therapy, limb amputation, and metronomic chemotherapy. Curative intent options include combining different modes of therapy such as surgery, radiation therapy, and chemotherapy. However, no matter the combination used, 80% of dogs with OSA die due to the high metastatic potential of the tumor.

Curative intent surgeries have traditionally involved limb amputation, but recently, more limb sparing procedures are being done with comparable survival times. In the limb sparing techniques, the tumor is removed with marginal soft tissue resection. A cortical allograft is then placed in the bone void; the bone is then plated in place. Complication rates for this procedure can exceed 50%, but for dogs with other orthopedic or neurologic function, it may be the best option. New techniques are being explored to decrease the rate of complications associated with the cortical allografts.

Since metastasis is the most common cause of death in dogs with osteosarcoma, the addition of chemotherapy into curative intent protocols is vital to longer term survival. They are used either in combination with surgery or radiation therapy in an attempt to decrease the metastatic rate. Cisplatin, Carboplatin and Doxorubicin are examples of agents currently used to help control metastatic disease. Their use markedly increases survival times beyond those of amputation or tumor removal alone.

Prognosis for patients with OSA is based on many factors. Poor prognostic indicators are animals under 7 years of age, large tumor volume, tumor location in the proximal humerus, elevated alkaline phosphatase (total and bone specific), failure of these levels to return to normal by 40 days post-operative, high tumor grade, and presence of metastasis. Survival times after treatments vary greatly and much research is currently being done in this area. Recently, a median survival time of 7 months was reported for dogs receiving radiation therapy along with chemotherapy; whereas a combination of surgery and chemotherapy showed more encouraging median survival rates of 235-366 days with up to 28% surviving two years after diagnosis.

-by Lori Fruit, Class of 2005

-edited by Dr. Leon Thacker, ADDL Director

References:

1. Ettinger and Feldman: 2000. Textbook of Veterinary Internal Medicine. WB Saunders, Philadelphia.
2. Liptack JM, WS Dernell, N Ehrhart, SJ Withrow: 2004. Canine Appendicular Osteosarcoma: Diagnosis and Palliative Treatment. *Compend Contin Educ Pract Vet* 26(3): 172-182.
3. Liptak JM et al: 2004. Canine Appendicular Osteosarcoma: Curative-Intent Treatment. *Compend Contin Educ Pract Vet* 26(3): 186-196.
4. Morrison, Wallace: 1998. Cancer in Dogs and Cats: Medical and Surgical Management. Lippincott Williams and Wilkins, Philadelphia.
5. Summers, Alleice: 2002. Common Diseases of Companion Animals. Mosby.
6. Tilley and Smith: 2000. The 5-Minute Veterinary Consult: Canine and Feline. 2nd ed. Lippincott Williams and Wilkins, Philadelphia.

ADDL NEWS



Dr. **Bill Van Alstine**, ADDL pathologist, has taken a position in the Veterinary Pathobiology department at Purdue as a pathologist in the Medical Discovery Resource Unit and will focus on coordinating research efforts throughout the Purdue campus. Dr. Van Alstine will remain at ADDL as a faculty pathologist on a limited basis.

ADDL serology technicians **Cheryl Parker** and **Cheryl Chapple** successfully completed the Brucellosis proficiency tests.

Response from Dr. Jim Hennegan, Indianapolis, IN to GDV article published in the Summer 2005 Diagnostic Forum.

"Nice article on acute GDV in summer 2005 issue. Having operated on over 80 GDV cases over 41 years as I was fortunate to attend to the #1 G. Dane kennel in U.S., I beg to differ with mortality rate being bandied about. I am sure it has improved in recent years; but 40-50% would be more accurate, when consideration of onset and 6 months post surgery. If treatment is not recognized and begun within 2 hours, the survival rate diminishes greatly and is a factor not recognized by many. I also found that relief of gastric pressure with a 2 inch gastric incision far more successful than fiddling around with small gauge needles (after several early failures). Of course, back in the early 60's and 70's, we were just beginning to recognize GDV.

Notes from Virology/Serology Section

The Virology/serology group would like to make you aware of new tests are currently being offered in this section. Two new ELISA serology tests which detect antibodies against swine influenza H1N1 and H3N2 are now available at a cost recovery price of \$4/sample.

An upgraded laboratory computer data-management system will be implemented in the next few weeks. This system will allow improved turnaround time for reporting results.

We are dedicated to providing the best service possible to our clients at all times. If you have any comments, suggestions, or questions, please feel free to contact me at any time at the ADDL.

Roman Pogranichniy, DVM, PhD
Head of virology/serology section
765-494-7440 or email
rmp@purdue.edu

Our goal in publishing the Diagnostic Forum is to provide you with current and useful information on disease diagnosis.

Please let us know if there is anything you'd like us to add to this newsletter.

Email Linda at yankovil@purdue.edu or phone (765-494-7448) with your ideas and/or suggestions.