



FROM THE DIRECTOR

H. Leon Thacker, DVM, PhD

Fall, what a great time of the year!. Harvest; crisp, clear days; new school year; frost and the passing of another season of mosquitoes. This year, the disappearance of the mosquitoes will be especially welcome as the vector of West Nile virus spread will also be gone for a few months. We've been busy with diagnosis of WNV primarily in horses and birds, but with recent findings in other species, we are receiving many

suspected cases in other species. From reports we have received from many practitioners, the WNV vaccine appears to be very effective in preventing the disease in horses and, although it has been reported in other species, it appears that WNV will be of only occasional consequence in species other than equine and avian. We have drawn up a protocol for handling WNV suspects in the Laboratories which will hopefully minimize the risk of exposure to our pathologists, microbiologists, support staff and students to the disease from animals and birds submitted for diagnosis. Although WNV is reported to be of very limited consequence in individuals with normal immune competence, it can be a severe or lethal disease for people or animals in immunity depressed status. The soon anticipated killing frosts will temporarily eliminate the mosquito population which is the primary means of transmitting the disease and there are a lot of horses in our state that have been vaccinated for the disease. We encourage all horse owners to vaccinate their horses against WNV; though the occurrence of the disease will no doubt be abated over the winter, it will be back with us with the resumption of mosquito season next spring. I expect the number of vaccinated horses in Indiana to reduce the incidence of the disease in horses in 2003 though the numbers of susceptible birds will likely serve as a viable reservoir for some time to come.

Although it is not in epidemic proportions, we should remain cognizant of the ever present threat of rabies in our domestic and wild animals. In our immediate area around West Lafayette, we have recently had an increase in the number of bats diagnosed with rabies. As bat rabies is likely the most lethal form of rabies for humans, this should be of concern and recognition.

Please note the new tests available in the ADDL. We are excited about the offering of these new methods for more rapid and definitive diagnostic means. Hope you have a most enjoyable fall season; we are here to assist you with your diagnostic needs.

Final Diagnosis <i>Fascioloides magna</i> in an elk spinal cord.....	1
<i>Rhodococcus equi</i> pneumonia in Foals.....	2
ADDL Schedule.....	4
Chronic Wasting Disease.....	4
Nitrate Toxicity.....	6
ADDL Staff News.....	7
On the Road.....	9
New PCR Tests at Purdue ADDL.....	10



FINAL DIAGNOSIS

Fascioloides magna in spinal cord

In each issue, we will feature a case submitted to ADDL that we hope will be of interest to you.

History: A 2 year old bull elk (*Cervus elavus*) was submitted dead for postmortem examination at the Purdue Animal Disease Diagnostic Lab. The animal was markedly emaciated and died following an acute onset of paraplegia.

Gross lesions: Findings at necropsy included marked infestation by *Trichuris* sp. Gross examination of multiple sections of formalin-fixed spinal cord revealed randomly distributed pinpoint, brownish-red foci both in the gray matter and white matter between thoracic vertebra 4 and lumbar vertebra 7. These lesions were more severe and widespread in the white matter. The liver was diffusely mottled red, and the cut surface revealed the presence of multiple black fibrotic tracts measuring 0.5-1.5 cm in diameter.

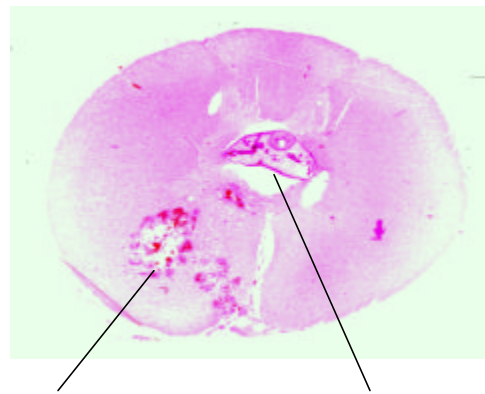
Histopathologic findings: Microscopic examination of affected segments of spinal cord exhibited irregularly shaped and-sized multiple foci of necrotic neuropil tissue. These lesions consisted of acute liquefactive necrosis and hemorrhage accompanied by moderate numbers of gitter cells, with occasional randomly scattered eosinophils and neutrophils. Many swollen eosinophilic axons (spheroids) and swollen myelin sheaths were present at the margins of necro-hemorrhagic foci. Blood vessels in the neighboring neuropil had hypertrophic endothelium and mild perivascular cuffing with lymphocytes and plasma cells. The leptomeninges in the ventral median fissure contained large numbers of lymphocytes and neutrophils and lesser numbers of macrophages, plasma cells, and eosinophils. In two sections, the central canal was poorly

defined, lacked ependyma, and contained transverse sections of immature fluke (marita) consistent with *Fascioloides magna*. Multiple fibrotic tracts with black pigment were present in the liver. One of the fibrotic tracts in the liver contained numerous operculated trematode eggs ranging in diameter from 40 –60 µm with thick amber to brown shells.

Discussion: *Fascioloides magna*, the large American liver fluke or deer liver fluke, is a common parasite of elk. The flukes are usually confined to the fibrotic cysts in the liver and, except for causing some liver damage, are of little clinical consequence. In this case, aberrant migration of the immature flukes was observed in the spinal cord and was considered a likely cause of the reported hind limb paralysis prior to death. The emaciation of this animal was considered to be due to marked gastrointestinal parasitism.

-by Dr. Alok Sharma, ADDL Graduate Student

Transverse section of elk spinal cord



Necro-hemorrhagic foci

Cross section of *Fascioloides magna*

Rhodococcus equi **Pneumonia in Foals**



Rhodococcal pneumonia is the most important life-threatening lower respiratory disease in young foals. The causative agent is *Rhodococcus equi*, a facultative intracellular pathogen with virulent and avirulent strains, is a common soil organism, and is also present in the intestinal tract of (healthy) horses. The major route of transmission is aerosolization via dust particles, occasionally followed by secondary intestinal infection due to swallowing of sputum containing the organism. However, a minor route of infection is primary intestinal infection which may lead to secondary hematogenous pulmonary infection. Concurrent helminthic infection of the intestine predisposes to intestinal infection with *Rhodococcus equi*. *R. equi* preferentially targets macrophages where it is able to survive and multiply, presumably by inhibition of phagosome-lysosome fusion and triggering the premature release of lysosomal contents.

R. equi infection is primarily observed in 2-4 month old foals. At this age, maternal antibodies wane, making foals susceptible to infection. In addition, foals with coprophagic behavior are predisposed to infection since *R. equi* depends on volatile fatty acids in herbivore manure for optimal multiplication. In addition, *R. equi* is capable of multiplication in the intestinal tracts of foals up to 12 weeks of age which allows the organisms to concentrate on farms where foals are raised. Although most farms are infected with *R. equi*, disease occurrence ranges from nonexistent on most farms to sporadic or endemic. Variable infection rates are associated with several factors, including environmental temperature, soil pH, strain virulence, and management factors.

Clinical findings Most cases of rhodococcal pneumonia occur in foals between two and four months of age.

Disease onset is insidious, and foals are generally able to compensate for the progressive loss of pulmonary function, making early clinical diagnosis difficult. Despite the chronicity of lung lesions, foals usually present with an acute onset of respiratory distress and/or sudden death. Observed clinical signs include anorexia, lethargy, slight mucopurulent nasal discharge, fever (101.5^o -104^oF), tachypnea, increased respiratory effort, and lack of response to common antibiotics. On auscultation, wheezes and crackles may be present and percussion may reveal areas of dull resonance associated with chronic abscessation. Coughing, if present, varies from moist to nonproductive, and may be intermittent or frequent.

Approximately 50% of pneumonic foals also present with ulcerative colitis. Clinical signs in foals with severe gastrointestinal involvement include diarrhea, weight loss and ascites. Immune-mediated polysynovitis is seen in approximately 1/3 of foals with lung lesions. In these foals, effusion is most common in the tarsal and stifle joints, and is not associated with lameness. An agent is rarely cultured from synovial fluid. Other uncommon manifestations of *R. equi* include septic arthritis and osteomyelitis, subcutaneous abscesses, and uveitis.

Clinical diagnosis: Clinical signs suggestive of *R. equi* infection include age of the foal, presence of fever, and lack of nasal discharge. Hyperfibrinogenemia is the most consistent laboratory finding. Thoracic radiographic findings include a prominent alveolar pattern characterized by discrete nodular or cavitory lesions consistent with abscesses.

Serologic tests that have been used in diagnosis include agar gel immunodiffusion (AGID), ELISA, and synergistic hemolysis inhibition. A major problem with serologic diagnosis is the widespread exposure of foals to *R. equi* in the environment, resulting

in antibody production which is not necessarily associated with infection. The presence of maternal antibodies may further confound interpretation, resulting in additional false positive tests.

Definitive diagnosis of Rhodococcal pneumonia is based on PCR, bacterial culture, and cytology of transtracheal wash (TTW) fluid. Presence of large gram positive pleomorphic organisms in TTW cytology is consistent with *R. equi* infection. Organisms are usually present in low numbers. *R. equi* can be isolated by aerobic culture, generally within 48 hours. RCR is a new method which is more rapid than bacterial culture and can differentiate between virulent and avirulent strains.

Postmortem diagnosis: Gross pulmonary lesions are consistent with multifocal to coalescing pulmonary abscesses and/or granulomas with consolidation and congestion of lung parenchyma; airways in affected regions may be clogged with mucopurulent exudates. Similar abscesses and/or granulomas may be found within tracheal lymph nodes. Histologically, lesions are composed of a necrotic central core with a collar of degenerate neutrophils. An outer zone of macrophages, occasional giant cells, and lymphocytes surrounds the core. The amounts of intralesional neutrophils is variable and is increased in older lesions. Lesions within the adjacent parenchyma include infiltration of bronchi, bronchioli, and alveolar spaces with macrophages and neutrophils in varying amounts.

Almost ½ of necropsied foals will show multifocal ulcerative typhlocolitis, often associated with abscesses and/or granulomas within mesenteric lymph nodes. On gross examination, the mucosa is thickened by infiltration with (numerous) macrophages, giant cells and neutrophils. There are sharply demarcated foci of coagulation necrosis with ulceration of the mucosal surface.

Gram-positive and partial acid-fast small rod-shaped bacteria consistent with *R. equi* can be detected within the cytoplasm of macrophages and giant cells by use of the

special stains Brown and Brenn and Ziehl Nelson.

Prevention and treatment: Screening methods to detect early disease on farms with a history of rhodococcal pneumonia include frequent physical examination, twice daily rectal temperature measurement, thoracic auscultation, and diagnostic imaging to detect early pulmonary lesions. Frequent removal of manure from foaling stalls and paddocks may help decrease environmental contamination and exposure to foals. Efforts to reduce population density and dust in the environment should be considered on large breeding farms with endemic *R. equi* pneumonia.

Transfusion of hyperimmune plasma, preferably in the first few days after birth and again in the third week of life, is the only method proven, though not failsafe, to prevent *R. equi* pneumonia. Oral administration of colostrums from immunized mares is not protective and effective vaccinations are currently not available.

Standard treatment of rhodococcal pneumonia is the combination of erythromycin and rifampin. The combination has synergistic activity and excellent penetration of pulmonary alveolar macrophages. Dosages range from 5-10 mg/kg of oral rifampin twice daily, and 10-37.5 mg/kg of oral erythromycin 3 times daily. Length of treatment may last from 30-60 days, depending on clinical response, return to normal laboratory values, and resolution of radiographic changes. Additional supportive therapy includes intravenous fluids, nasal oxygen for foals with respiratory distress, NSAIDS, and a cool environment.

-by Kim, Maratea, Class of 2003

-edited by Dr. Sandra Schoeniger, ADDL

Graduate student

References on page 4

References

1. Bertone JJ, 1998. Pneumonia and other disorders associated with *Rhodococcus equi*. Equine Internal Medicine, 970-980.
2. Cohen ND, Chaffin MK, and RJ Martens, 2000. Control and prevention of *Rhodococcus equi* pneumonia in foals. Compend Contin Educ Pract Vet, 22: 1062-1069
3. Giguere, S. and JF Prescott, 1997. Clinical manifestations, diagnosis, treatment, and prevention of *Rhodococcus equi* infection in foals. Vet Microbiol, 56: 313-334.
4. Prescott, JF, 1991. *Rhodococcus equi*: an animal and human pathogen. Clin Microbiol Rev 4: 20-34.
5. Prescott JF and AM Hoffman, 1993. *Rhodococcus equi*, Vet Clin North Am Equine Pract. 375-384



Chronic Wasting Disease (CWD)

In 1967, a syndrome known as chronic wasting disease was first described in several wildlife facilities in Colorado and Wyoming. These facilities used deer from captive does, captured pregnant does, and orphaned fawns for nutritional, metabolic and disease studies. In a 12 year period, 53 mule deer and one blacktail deer in these facilities showed signs of chronic wasting disease. The affected animals were young adults that had been within captivity for 2.5-4 years. These animals had minimal contact with wild ruminants, domestic ruminants or free ranging small mammals such as rodents and small furbearers.

Chronic wasting disease is now found in captive and wild elk and deer in both the United States and Canada. The disease has been demonstrated in Rocky Mountain elk, mule deer, white-tailed deer, and black-tailed deer. On many occasions, affected cervids have been in direct or indirect contact with other ruminants such as cattle, sheep, and goats, with no evidence of disease transmission to these other ruminant species. There is also no evidence of CWD being related to Transmissible Spongiform Encephalopathies in humans. For years, the disease has occurred endemically in free ranging elk and deer in northern Colorado, southern Wyoming, and southwestern Nebraska. No animals in these areas are permitted to be moved to other research facilities or translocated for repopulation. Recently, the disease has also been found in free ranging deer and/or elk in Wisconsin, South Dakota, and New Mexico. Numerous positive animals have also been identified on farm raised elk herds. They include farms located in South Dakota, Nebraska, Colorado, Oklahoma, Montana, Kansas and the Canadian province of Saskatchewan.

Purdue ADDL and Heeke ADDL will be closed on the following University holidays

- November 28-29..... Thanksgiving
- December 25-27.....Christmas
- January 1..... New Year's Day
- January 20..... Martin Luther King



These farms were quarantined and many have been depopulated, slaughtered and tested.

The signs of CWD are numerous and vary in severity and time of onset. Males, females and castrates are affected equally. The onset of signs can occur during any season of the year. The signs may start with listlessness, progressive weight loss, and depression that lasts over a 2 week – 8 month period of time. Many deer develop signs of polyuria, polydipsia, excess salivation, odontoprisia, flaccid facial muscles, drooping ears, lowering of the head, and terminal anorexia. Many animals have changes in behavior which may include a lack of awareness that is seen by a lowered head and fixed stare for a period of minutes, followed by a return to a normal state of consciousness. These signs progress until the animal develops secondary complications, such as pneumonia, that lead to the death or euthanasia of the animal. Clinical pathological findings are non-specific and are generally related to the secondary infections.

Many pathologic changes are seen on necropsy. Gross pathological changes are varied and often non-specific. The most common gross finding is severe emaciation; however, some animals show no abnormalities at all. Many other findings are due to secondary complications such as pneumonia, abscesses, enteritis, and parasitism. Histopathologic changes of the central nervous system are the most specific finding in affected animals. These changes include microcavitation (spongiform transformation) of the neuropil, intracytoplasmic vacuoles in neuronal perikaryons and neuronal degeneration. The spongiform transformation was seen in the gray matter of the spinal cord, medulla oblongata, pons, mesencephalon, thalamus, hypothalamus and cerebral cortex. The histologic lesions are most consistently found in the “obex” region of the medulla oblongata (caudal brain stem), and it is this portion of the brain that is routinely tested for CWD.

Because of the similar lesions, CWD was linked to a category of other transmissible spongiform encephalopathies including scrapie, bovine spongiform encephalopathy, transmissible mink encephalopathy, Kuru and Creutzfeldt-Jakob disease. These diseases are caused by unique agents called prions. The incubation period of the prions is from weeks to years; for this reason, they are known as a “slow virus” disease. However, prions are an unconventional agent in that they differ from viruses in many ways. They facilitate the use of normal cellular pathways for replication. However, no evidence of nucleic acid has been found in conjunction with any prions. They are very resistant to many agents that are used to neutralize many viruses such as ultraviolet radiation, ionizing radiation, ultrasonication, proteases, nucleases, heat, formaldehyde, chloroform and ether. It is believed that prions are an abnormal protein made from a normal protein-making gene. The normal gene, PrP gene, encodes the formula for the production of a normal protein called the “prion protein”, PrP. The protein attaches to the outer layer of the plasma membrane lipid bilayer. The function of the “prion protein” is not known. The “prion protein” is normally in an α -helix formation. The abnormal isoform forms a β -pleated sheet that is protease resistant and, therefore, forms the characteristic protein plaques that are often seen ultrastructurally in many of these diseases. How the ingestion of an abnormal protein can facilitate the transformation of a normal gene to make an abnormal protein is not yet known.

Because of its similarity to bovine spongiform encephalopathy and its apparent spread to wild deer populations outside of the endemic area, there is increasing public concern about CWD. Because of this concern, Indiana now requires all captive elk herds to be registered with the state and a number of restrictions have been placed on the movement of captive elk. If you have any questions about the management or transport of elk you are encouraged to contact the State Veterinarian’s office (317-

227-0300). To date, there is no evidence that CWD exists in Indiana. To give us greater confidence that Indiana is free of CWD, the ADDL will cooperate with the State Veterinarian's office and the Indiana DNR this fall in a survey of hunter-killed deer. It is hoped that we will continue to find no evidence of CWD in Indiana; however, if we do, it is important to keep in mind that this disease is not known to pose a threat to domestic cattle or humans.

If you have questions about the fall deer survey, you are again encouraged to contact the Office of the State Veterinarian. If you would like to learn more about chronic wasting disease, an excellent review has been made available by the Southeastern Cooperative Wildlife Disease Study (SCWDS) on the internet at www.uga.edu/scwds/briefs.htm. After accessing the site, click on Volume 18, issue 1.

-by Jill Rietdorf, Class of 2002

-edited by Dr. Duane Murphy,

ADDL Pathologist

References:

1. Cotran R, Kumar V, Collins T: 1999. Transmissible spongiform encephalopathies (prion diseases). Robbins Pathologic Basis of Disease pp 1323-1326.
2. Jones TC, Hunt RD, King NW: 1997. Prions. Vet Path pp 360-366.
3. USDA, APHIS. October, 2001. www.aphis.usda.gov/pa/pubs/fscwd.html
4. Williams ES, Young S: 1980. Chronic wasting disease of captive mule deer; a spongiform encephalopathy. J Wildl Dis 16:89-98.
5. Williams ES, Young S: 1982. Spongiform encephalopathy of Rocky Mountain elk. J Wildl Dis 18:465-471.



NITRATE TOXICITY

The primary nutrient form of nitrogen in most soils is nitrate which is a normal compound found in many plants. It can be found normally in various grazing and forage crops, soil, and water. Under certain circumstances, nitrates can accumulate to abnormally high levels and become very toxic to ruminants. Nitrate accumulation in plants varies widely between species and is influenced by several factors, especially those factors that tend to limit the growth of the plant while still allowing for the uptake of nitrate. One of the most important factors affecting nitrate accumulation in plants is drought, although frost damage, treatment of crops with herbicides and shading can also result in higher than normal levels in some forages. Water can also serve as a carrier for nitrate, gathering it from the soil, fertilizers, runoff from feedlots or sewer systems as well as from industrial sources. Nitrate itself is not overly toxic to animals; however, when nitrate is reduced to nitrite by rumen microflora, it becomes very toxic. The conversion of nitrate to nitrite occurs via microbial reduction in the rumen, in moist feeds prior to their consumption, or in water that is contaminated with organic matter. Nitrate reduction and associated toxicity in ruminants will be the primary focus of this article.

Sources of nitrate

There are several plant species that may accumulate nitrate, including the Brassica plants, green cereal grains (barley, wheat, rye and maize), sorghum and Sudan grasses, corn, beets, rape, docks, sweet clover and nightshades. Application of large amounts of fertilizer or drainage from fertilized fields and contaminated water sources can also serve as a source for nitrate.

Our address has changed to

Animal Disease Diagnostic Laboratory
406 S. University
Purdue University
West Lafayette, IN 47907

Drought can also allow accumulation of nitrate in certain plants.

Species affected

The toxic principle for all animals is nitrite. Nitrate, prior to being reduced to nitrite, is not overtly toxic to non-ruminant species. Nitrite is essentially equally toxic to both ruminant and non-ruminant species. Toxicity in ruminants is primarily seen following the consumption of high amounts of nitrate, which is subsequently reduced to nitrite by rumen microbes. Cattle, sheep and goats are the species that are most commonly affected by nitrate poisoning, with neonatal animals being at greater risk.

Mechanism of toxicity

Plants absorb nitrate which is normally converted to nitrite by the nitrate reductase system and incorporated into amino acids and proteins. Genetic or environmental factors that interfere with or inhibit the function of the nitrate reductase system allow for nitrate to accumulate in the plant. For example, in response to stressful conditions, sorghum species have reduced reductase activity. Drought and conditions of reduced sunlight will also decrease the activity of the nitrate reductase system.

Despite the decreased activity, nitrate is continuously absorbed by the plant and accumulates to abnormally high levels. Ruminants consuming these plants convert the nitrate to nitrite and then to ammonia. Nitrate toxicity is a function of the amount and rate at which nitrate is consumed. When the animal consumes a normal forage diet containing large amounts of nitrate, the conversion of nitrite to ammonia becomes the limiting factor allowing nitrite to accumulate to toxic levels. Toxicity occurs following the absorption of nitrite into the blood which oxidizes iron in hemoglobin from the ferrous (+2) to ferric (+3) state. The resultant methemoglobin has a very poor affinity for oxygen which greatly reduces the oxygen-carrying capacity of red blood cells. Death from anoxia may occur if 70-80% of the hemoglobin is converted to methemoglobin.

Clinical signs, necropsy findings and diagnosis

Nitrate toxicity is generally acute to subacute with signs seen within a few hours to a few days following consumption of large amounts of nitrate. Common clinical signs seen include rapid but weak pulse, muscle tremors, tachypnea, blue-grey mucous membranes, ptilyism, depression, weakness, staggering gait, disorientation, frequent urination and a subnormal body temperature. If left untreated, the condition rapidly deteriorates to prostration, coma and death. Death usually occurs within a few hours to days following onset of clinical signs.

High levels of methemoglobin can be noted at necropsy due to the presence of a chocolate-brown discoloration of the blood in about one half of the cases of nitrate poisoning. When present, this unique discoloration is also evident throughout the mucosa, viscera, and sometimes the urine. Presently, feed, serum and aqueous humor should be collected for chemical analysis. Feed nitrate concentrations of approximately 1.0% or greater are cause for concern. At postmortem, aqueous humor or an entire eyeball should be submitted. Methemoglobinemia, caused by nitrate/nitrite toxicity, must be differentiated from that due to intoxication by chlorates and plants such as onions.

Diagnosis is based on a history of ingestion of feed containing high levels of nitrates, clinical signs and, if present, chocolate-brown discoloration of the blood. All suspect feed and water should be submitted for chemical analysis along with necropsy samples as previously stated.

Treatment and Prevention

Methylene blue is a specific treatment for nitrate toxicity. It causes a rapid conversion of methemoglobin to hemoglobin. The dose of methylene blue is reported as 4-30 mg/kg IV of a 1% solution to be given as soon as clinical signs are identified. However, methylene blue is not approved for use in food animals. In addition, the stress associated with collecting, restraining and treating animals with severe methemoglobinemia must be considered. Identification and removal of the source of

nitrate is indicated as well. The 9th edition of Veterinary Medicine by Radostits et al reports that less than 0.6% of nitrate in the total diet is recommended. They also recommend that cows not be grazed on feed that contains more than 1% nitrate and slightly less when the cattle are not grazing the feed. Identifying the nitrate source and reducing the exposure is the key to controlling nitrate toxicity. When it occurs, however, rapid diagnosis and prompt treatment are necessary to prevent severe mortality loss.

-by Cody Wrathall, Class of 2001
-edited by Dr. Steve Hooser, ADDL
Chief of Toxicology

References

1. Roder JD: 2001. *Veterinary Toxicology*. Texas Tech Univ Health Sci Center. Butterworth-Heinemann
2. Radostits M Otto et al: 2000. *Veterinary Med 9th ed*. Harcourt
3. Smith PB: 1996. *Large Animal Internal Medicine 2nd ed*. Mosby-Year Book Inc.
4. Rebhun, CW, Guard C and Richards C: 1995. *Diseases of Dairy Cattle*. Williams & Wilkins
5. Church DC: 1993. *The Ruminant Animal: Digestive Physiology and Nutrition*. Waveland Press, Inc.
6. Andrews AH et al: 1992. *Diseases and Husbandry of Cattle*. Blackwell Scientific Publications
7. 1991. Nitrate Poisoning and Feeding Nitrate Feeds to Livestock. Agdex 400/60-1 <http://www.agric.gov.ab.ca/agdex/400/0006001.html>
8. Stanton TL. Nitrate Poisoning. Colorado State University Cooperative Extension. <http://www.ext.colostate.edu/pubs/livstk/01610.html>
9. Smith J and Guthrie L. Nitrate Toxicity and Prussic Acid Poisoning in Dairy Cattle. Univ of Georgia College of Agriculture and Environmental Sciences Cooperative Extension Service. <http://www.ces.uga.edu/pubcd/b1153-w.html>
10. Kvasnicka B and Krysl LJ. Nitrate Poisoning in Livestock. Cattle Producers Library CL 620. <http://www.forages.css>.

orst.edu/To...Grasses/Animal Issues/Nitrate.
Html

From the ADDL Toxicology Section

Corn silage and sorghum/sudan grass hay can accumulate sufficient amounts of nitrates to poison livestock (particularly ruminants). Nitrate accumulation in these forages occurs most often in heavily fertilized fields and under drought conditions. A diet consisting of greater than 1% nitrate can potentially result in nitrate poisoning in ruminants. Clinical signs of nitrate toxicosis occur when blood methemoglobin concentrations are between 30 and 40%. The most common abnormal signs are dyspnea, weakness, ataxia and terminal convulsions. Death occurs when blood methemoglobin concentrations exceed 80-90%. Samples to submit when nitrate poisoning is suspected are feed, forage, hay, and water. From animals, frozen samples of plasma, urine, and an eyeball (vitreous humor) should be collected and submitted for nitrate analysis.

Management suggestions for helping to prevent nitrate poisoning include:

1. If possible, do not feed forages high in nitrates.
2. If the forage is suspected of possibly being high in nitrates, submit a representative sample for testing.
3. When harvesting suspect forages such as corn, raise the cutter bar approximately one foot since most of the nitrate accumulates in the lower portion of the stalk.
4. Ensile the material and do not feed for at least 3 weeks until the ensiling is completed. Ensiling will decrease the total nitrate content. Be careful of potentially dangerous nitrogenous gases produced by the ensiling process.

Continued on page 9

5. Drying does not appreciably decrease the amount of nitrate in the forage. Therefore, even cured grass (sorghum X sudan hybrids particularly can accumulate large quantities of nitrates) with a high nitrate content will be hay with a high nitrate content.

6. If feeding a suspect forage, also feed good quality carbohydrate feed (approximately 2 pounds of grain per 450 lb body weight.)

7. Gradually introduce suspect feeds into the diet and feed several times per day in small amounts rather than all at once.

8. Young, stressed and unhealthy animals are more susceptible to nitrate poisoning.

9. Be sure that the nitrate concentration in the drinking water is below a toxic level. Generally, water nitrate levels of 45 ppm or less are considered safe.

-by Jane Likens, BS, Toxicology Technician
Christina Wilson, MS, Assistant Chemist
Robert Everson, PhD, Analytical Chemist
Stephen Hooser, DVM, PhD, Toxicologist



ADDL STAFF NEWS

Congratulations to former ADDL graduate students **Drs. Kaori Sakamoto, Marlon Rebelatto, Jan Lacey, and Melanie Greeley** for their recent recognition as Diplomates of the American College of Veterinary Pathologists. These pathologists successfully completed the ACVP board examination in September, 2002.

Congratulations to Serology technician **Brenda Turner** for successfully completing the Bluetongue and Equine Infectious Anemia proficiency tests.



ON THE ROAD

Drs. Ching Ching Wu and Tsang Long Lin participated in the 2002 International Union of Microbiological Societies Congress in Paris, France, July, 2002.

Dr. Leon Thacker participated as a Purdue University representative to the National Agriculture Biosecurity Center Consortium of Kansas State University, Texas A&M, and Purdue University, Kansas City, Missouri, July, September, 2002.

Drs. Leon Thacker, Ching Ching Wu, Steve Hooser, Greg Stevenson, Robert Everson, Randy White, Bill VanAlstine, Duane Murphy and Christina Wilson, Steve Vollmer and Linda Hendrickson attended the annual American Association of Veterinary Laboratory Diagnosticians meeting in St. Louis, Missouri, October, 2002.

Drs. Zheko Kounev, Ching Ching Wu and Tom Bryan attended the North Central Avian Disease Conference in Minneapolis, MN, October, 2002

New PCR Tests at ADDL

The molecular diagnostic section of ADDL, under the direction of Dr. Ramesh Vemulapalli, has adapted or developed 10 new PCR tests that are now available at ADDL. These PCR tests are in addition to the following tests that were previously adapted or developed by the bacteriology diagnostic section under the direction of Dr. Ching Ching Wu: *Lawsonia intracellularis*, *Brachyspira hyodysenteriae*, *Brachyspira pilosicoli*, *Salmonella sp.*, *E. coli* virulence typing, *Clostridium perfringens* typing, *Clostridium difficile* toxins, *Listeria monocytogenes*, *Mycobacterium paratuberculosis*, West Nile Virus (for birds), Infectious Bursal Disease virus, Turkey Coronavirus, *Renibacterium salmonarium* and *Myxobolus cerebralis*. More new PCR tests will be offered at ADDL. A current list of available PCR tests is in Table 1 and a frequently updated list can be viewed on the ADDL web site at <http://www.addl.purdue.edu>.

Types of PCR Tests

A test simply designated as “PCR” is a polymerase-chain-reaction test to detect DNA and is composed of 3 basic parts:

- 1) extraction of the DNA from the sample,
- 2) Addition of sample DNA, one set of DNA nucleotide primers and other reagents to a PCR-cycler machine for amplification of target DNA and,
- 3) Detection of target DNA by gel-electrophoresis.

A test designated as RT-PCR is a reverse-transcriptase PCR test to detect RNA and is composed of the same 3 basic parts as PCR and an additional step using reverse-

transcriptase enzyme to synthesize complementary DNA from the target RNA. The complementary DNA is then run in the PCR test. Nested PCR is a modification that uses 2 sets of nucleotide primers and 2 complete cycles of amplification; the second cycle of amplification further amplifies a target fragment of DNA originating within an already amplified larger target fragment of DNA. Nested PCR results in higher sensitivity than simple PCR or RT-PCR and is used for diseases that have very little target nucleic acid in tissue samples.

PCR Testing by Request Only

PCR tests are run by request only. Additional charges will be incurred for each PCR test that is run on samples that are mailed to ADDL and on tissues collected during necropsy examination at ADDL (see below). When PCR tests are desired for various agents, each desired test must be clearly requested on the ADDL submission form at the bottom of the first page under either “Clinical Diagnosis” or “Other specified tests”. Alternatively, only for animals submitted for necropsy, permission may be granted in writing as follows, “Please run any PCR tests that are deemed necessary for diagnosis”.

Large Numbers of Samples by Prior Arrangement Only

Prior arrangements are required for submissions of >10 samples from the same source on the same day for PCR testing. Please contact us at the general ADDL telephone number (765-494-7440) and you will be forwarded to the appropriate laboratory.

Continued on p. 11

Charges for PCR Testing

The cost of each PCR test is as listed in Table 1 and is determined by the type of each test. PCR and RT-PCR tests are \$15 and nested PCR tests are \$25. Cost is doubled for cases originating out of state. For whole carcasses submitted for necropsy, the cost of each PCR test is added to the usual accession and necropsy fee.

Special Care Needed in Collection of Samples for PCR Testing

PCR tests provide unprecedented sensitivity and specificity. However, due to the extreme sensitivity of PCR, cross-contamination of samples is common. It is best to collect samples with disposable instruments (plastic tableware often works well) into sterile whirl-paks. Optimum sample size per test is approximately 10-15 grams or mls (1/2-1.0 cubic inch). Eliminate air, roll the tops down and seal by folding tabs. Avoid use of instruments that may be contaminated from previous use. Whirl-pak bags are available for purchase at ADDL (\$5.00/50) or through various scientific suppliers such as VWR Scientific Products (1-800-932-5000), PGC Scientifics (1-800-424-3300) or Fisher Scientific (1-800-766-7000).

Special Packaging Required for PCR Testing

Tissues sent for PCR must be packaged separately in whirl-paks and clearly labeled with which tissues are included and tests requested, e.g. "Liver, Kidney" "for Lepto PCR". Samples should be shipped overnight on ice packs in an

insulated shipping container. All tissue samples in a single bag will be pooled and a single PCR test will be run for each requested agent. If the same PCR test is desired on tissues from different animals or from different tissues from the same animal, then separate samples in separate whirl-paks must be submitted.

Recommended Uses for Various PCR Tests

PCR tests may be used as the primary test to detect organisms when cost is not a constraint. PCR tests also provide more rapid turn-around and/or greater sensitivity for some fastidious organisms such as *Salmonella sp.*, *Listeria monocytogenes*, *Lawsonia intracellularis*, *Brachyspira sp.*, *Mycoplasma gallisepticum* and *Mycoplasma synoviae*. Due to the elegant sensitivity of PCR tests, they are the test of choice when little of the target organism is expected in tissue and maximum sensitivity is required. PCR tests are the choice at Purdue ADDL for diseases that pose serious health threats to personnel since the first step in PCR tests inactivates most infectious organisms. These zoonotic agents include *Chlamydia sp.* and West Nile Virus. The elegant specificity of PCR allows for differentiation of closely related organisms and is the only test available at Purdue ADDL for differentiation of TGE and PRCV, of H1N1, H1N2 and H3N2 group A Influenza viruses and of strains of *E. coli* and *Clostridium perfringens*. PCR is also the best test for detecting certain infectious agents in fetal tissues where *in utero* autolysis renders them undetectable by other tests. We recommend PCR tests for PRRS virus,

Leptospira sp. and *Chlamydia sp.* when indicated by clinical history on fetuses. We feel that the PCR test for Leptospirosis the only reliable test to confirm infection with *Leptospira sp.*

All PCR tests performed at Purdue ADDL are based upon published protocols in peer-reviewed scientific literature and have been validated with known positive and negative samples. PCR detects specific segments of nucleic acid from the target organism. As such, a true positive test indicates the presence of specified nucleic acid from the target organism, not viable organisms. Unless specifically designed to do so, PCR tests do not differentiate vaccine from field strains of organisms. The high specificity of PCR tests means that false-positive tests due to improper test function is unlikely. False-positive PCR tests are most commonly a result of contamination of the sample with spurious target nucleic acid during sample collection or during the performance of the test. Extreme care is taken at Purdue ADDL to prevent contamination during the performance of PCR tests. Contamination of samples is more likely during collection of samples under field conditions. Positive results must always be evaluated considering the methods used for sample collection. If disposable instruments were not used to collect samples, positive results should be cautiously interpreted. The high sensitivity of PCR also means that true-positive results occur frequently in samples from clinically normal animals in endemically infected populations. It is therefore important to interpret the significance of true positive results in light of consistent clinical disease or lesions. Although PCR tests are very sensitive, false-negative results can occur due to the nature of the sample.

For example, fecal samples contain enzyme inhibitors that may interfere with the enzymes used in PCR tests resulting in reduced sensitivity. Intestinal mucosa scraped from regions with gross lesions is always a better sample than feces for PCR testing. Sensitivity is also reduced by sub-optimal choice of tissues/samples. For example, in cases of nervous listeriosis in ruminants, lesions and organisms are principally in certain cranial nerves and the medulla. In such cases, if forebrain or mid-brain is submitted instead of medulla for PCR testing, false-negative tests are common.

Your Comments are Appreciated

As we continue to add tests and strive to increase the quality of our science and service, we welcome your comments and constructive suggestions.

-by Dr. Greg Stevenson, Head of Pathology

Dr. Ramesh Vemulapalli, Head of Molecular Diagnostics

Dr. Ching Ching Wu, Head of Bacteriology



Table 1: PCR Tests Available at Purdue ADDL

Organism	Test Type	Cost	Suggested Samples
Group A Influenza viruses	RT-PCR, nested	\$25	Lung
Influenza viral typing: H1N1, H1N2, H3N2	RT-PCR, 2 tests	\$25	Viral isolates only; first requires virus isolation on lung
BVD1 and BVD2 viruses	RT-PCR, nested	\$25	Lymph nodes, spleen
PRRS virus	RT-PCR, nested	\$25	Serum, spleen, lung
TGE virus (differentiates from PRCV)	RT-PCR, nested	\$25	Small intestine, feces
<i>Leptospira sp.</i> (all pathogenic species)	PCR	\$15	Urine, liver, kidney
<i>Chlamydia sp.</i> (genus specific)	PCR	\$15	Placenta, liver
<i>Chlamydia psittaci</i>	PCR	\$15	Placenta, liver, other
<i>Neospora caninum</i>	PCR	\$15	Any tissue with lesions
West Nile virus (mammals)	RT-PCR, nested	\$25	Brain and spinal cord
West Nile Virus (avian)	PCR	\$15	Kidney, heart, brain, liver, spleen
Infectious Bursal Disease virus	PCR	\$15	Bursa
Turkey Coronavirus	PCR	\$15	Small intestine, feces
<i>Mycoplasma gallisepticum</i>	PCR	\$15	Lung, trachea, oviduct, swabs from sinuses, choana, and trachea
<i>Mycoplasma synovium</i>	PCR	\$15	Lung, trachea, oviduct, swabs from sinuses, choana, trachea and joints
<i>Lawsonia intracellularis</i> ¹	PCR	\$15	Ileal mucosa, feces
<i>Brachyspira hyodysenteriae</i> ²	PCR	\$15	Cecal and colonic mucosa, feces
<i>Brachyspira pilosicoli</i> ³	PCR	\$15	Cecal and colonic mucosa, feces
<i>Salmonella sp.</i> ⁴ (genus specific)	PCR	\$15	Intestinal mucosa, feces, other tissues as indicated
Enteric panel (1-4 above)	PCR (multiple)	\$30	Intestinal mucosa, feces
<i>E. coli</i> virulence typing panel: F18, 987P and F41 pili; eae attachment gene; LT, StaP, Stb, and Stx2e toxins	PCR (multiple)	\$30	Bacterial isolates only; first requires bacterial culture
<i>Clostridium perfringens</i> typing panel: α , β , ϵ , ι and β 2 toxins; enterotoxin	PCR (multiple)	\$30	Bacterial isolates only; first requires bacterial culture
<i>Clostridium difficile</i> toxins A and B	PCR	\$15	Frozen colonic contents from animals with minimal autolysis
<i>Mycobacterium paratuberculosis</i>	PCR	\$15	Mucosa from ileum, colon, ileocolic valve, mesenteric lymph nodes
<i>Listeria monocytogenes</i>	PCR	\$15	Medulla oblongata
<i>Renibacterium salmonarium</i>	PCR	\$15	Kidney
<i>Myxobolus cerebralis</i>	PCR	\$15	Hemi-section of the head

DIAGNOSTIC FORUM

DIAGNOSTIC FORUM is a quarterly newsletter of current services, regulations and research projects involving the ADDL which may be of interest to Indiana veterinarians and animal owners. It is our intention that the information provided will serve you. To know how successful we are, we would like to hear from you. Please send your comments, suggestions, requests and questions to: Diagnostic Forum Editor, Animal Disease Diagnostic Laboratory, 406 S. University, Purdue University, West Lafayette, IN 47907-1175.

ADDL SECTION HEADS AND PATHOLOGISTS

Director: H.L. Thacker, DVM, PhD	Histology: Randy White, DVM, PhD
Assistant Director: Steve Hooser, DVM, PhD	Pathology: Greg Stevenson, DVM, PhD
Assistant to Director: Linda Hendrickson, BS, MA DVM, PhD	Molecular Diagnostics: R. Vemulapalli,
Avian: Tsang Long Lin, DVM, PhD	Serology: Karen Crane
Bacteriology: Ching Ching Wu, DVM, PhD	Toxicology: Stephen Hooser, DVM, PhD
Business Office: Lynn Grimes	Virology: Mary Woodruff, BS, MS
Computer: Steve Vollmer, BS	Heeke ADDL: Tom Bryan, DVM Duane Murphy, DVM, PhD
Veterinary Pathologists: Christine Hanika, DVM, PhD Dan Harrington, DVM, Ph Tsang Long Lin, DVM, PhD Bill VanAlstine, DVM, PhD	