



FROM THE DIRECTOR
H. Leon Thacker, DVM, PhD

Good day from ADDL. As this is being written, the weather here has taken a turn to the frigid category. With these ambient temperatures, the nutrition requirements of our animals so exposed are markedly increased. This, along with the shortage of feed production brought on by shortage of rainfall during the past growing season are expected to have bad effect of some of our animal populations. High grain prices and low roughage supplies are a bad combination.

I am saddened to report that Dr. Greg Stevenson will be leaving ADDL the end of February to join a ministry to college campuses as director of outreach to faculty and content development. Greg has provided 17 years of capable and dedicated service to ADDL and to animal owners of Indiana as well as most valuable teaching to students, colleagues and animal owners. He will be missed. A search committee has been appointed to select a replacement for Greg's position; the committee includes members from the ADDL faculty, the School of Veterinary Medicine faculty, Department of Animal Sciences and an Indiana private veterinary practitioner. A search committee has also been selected and chaired by SVM Dean Willie Reed to identify a new director of ADDL as I will be stepping aside as ADDL director August 1, 2008.

We recently completed immunohistochemistry testing of samples from 610 white tail Indiana deer collected by the Indiana DNR for chronic wasting disease. All of these samples, as well as several thousand tests run in previous years for CWD from Indiana deer were "no resistant prions detected". To date, no CWD has been found in the Indiana deer or captive elk populations.

Our laboratory continues to find swine in Indiana herds newly positive for porcine respiratory and reproductive syndrome (PRRS). This is likely the most economically significant infectious disease of swine in Indiana as well as elsewhere in the U.S.

Our toxicology laboratory has received many requests to conduct analyses for bone marrow fat as a quantification of malnutrition or neglect as various animals' terminal condition. The ADDL tox lab developed this test and subsequently established normal test values for various animals so that the bone marrow fat values may be used as a defined measure of an animal's terminal nutritional status. The tox lab also developed chemical analysis for juglone, the toxic principle of walnut toxicity (laminitis) of horses. Numerous requests for this analysis have also been received.

The ADDL was recently invited to join the national Food Emergency Response Network in the areas of microbiology and toxicology. With being a member of the FERN, our respective laboratory sections are required to pass periodic check tests for various microbial organisms and potential food toxicants so that ADDL will in turn be available to assist with food testing in the event of a catastrophic local or national food contamination event. We hope that our services are never needed for such an event.

In closing, I hope you can stay warm and enjoy Indiana winter. If there are things we can improve to better serve your veterinary diagnostic needs, please do not hesitate to let me know.

| | |
|---|---|
| Final Diagnosis: Epizootic Hemorrhagic Disease..... | 1 |
| Hepatic Lipidosis in Toy Breed Dogs..... | 3 |
| ADDL Schedule..... | 3 |
| Eastern Equine Encephalitis..... | 4 |
| ADDL News..... | 6 |
| Swine Influenza..... | 6 |
| Antibiotic sensitivities..... | 8 |

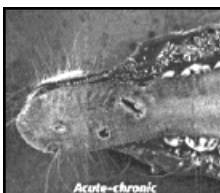
Final Diagnosis: Epizootic Hemorrhagic Disease

In each issue, we feature a case submitted to ADDL



History: A 1.5 year old White-tailed buck, from a farm of approximately 60 deer, was submitted to the ADDL for necropsy in early September, 2007. The buck had a three day history of ptyalism and foaming at the mouth. The farmer also reported that, since becoming ill, this deer often dipped its mouth in the water trough. The deer died after three days of illness.

Gross findings: Multiple, dark red, variably-sized and irregularly-shaped but well-demarcated, ulcers were scattered over the surface and sides of the tongue. Petechial hemorrhages were scattered throughout esophageal and tracheal mucosa. Pulmonary interlobular septa were expanded by gelatinous edema; pulmonary parenchyma was diffusely congested. Thin strands of fibrin stretched between pleural surfaces and lung lobes. The reticulum was diffusely dark red to purple transmurally, and was well-demarcated from the adjacent normal rumen. The abdomen contained approximately 300 ml of dark red, watery fluid.



Histologic findings: Glossal mucosa was segmentally ulcerated. Underlying muscle contained broad swaths of coagulative necrosis. Blood vessel walls throughout the tongue were infiltrated by neutrophils and few histiocytes. Severely affected vessels had diffuse loss of endothelial cells, necrotic medial myocytes, and sub-intimal erythrocytes. Adventitia surrounding blood vessels was expanded by clear edema fluid and hemorrhage. Few blood vessels contained hyalinized, eosinophilic material within the vessel wall, indicating fibrinoid change. Fibrin thrombi filled many vessel lumina. Thus, histologic changes were consistent with vasculitis, thrombosis, infarction, ulceration, and hemorrhage.

The reticulum was diffusely ulcerated. Blood vessel walls were infiltrated by neutrophils and few histiocytes; myocytes in the tunica media contained pyknotic and karyorrhectic nuclei. Few blood vessel walls were effaced by fibrinoid material, leukocytes, and necrotic cell debris. Erythrocytes effaced much of the tissue. The changes were consistent with vasculitis, infarction, and hemorrhage.

Other histologic changes corresponded with the previously described gross lesions, including fibrinous pleuritis and tissues with multiple petechial hemorrhages.

Ancillary findings: Spleen, lymph node, lung, tonsil, and liver were submitted for Epizootic Hemorrhagic Disease (EHD) virus fluorescent antibody testing and virus isolation. Multiple tissues were submitted in order to maximize the chances of isolating virus. Consequently, EHD virus was isolated from lung, lymph node, and spleen. FA for EHD virus was negative on all tissues.

Discussion: Epizootic hemorrhagic disease of deer is an often fatal disease caused by a double-stranded RNA orbivirus, and transmitted by gnats in the family *Culicoides*. Epizootic hemorrhagic disease virus is closely related to the orbivirus that causes bluetongue in cattle and sheep. There is serologic cross-reactivity between some serotypes of EHD virus and bluetongue virus. Bluetongue virus can also affect deer, and has been isolated alongside EHD virus from epizootics in North America. Likewise, cattle can become infected with EHD virus and exhibit mild clinical disease which rarely results in death. Lesions in cattle can include oral erosions, lameness/stiffness, and teat erosions. Epizootic hemorrhagic disease virus serotypes 1 and 2 have been implicated in epizootics of deer in the US, with EHD type 2 most often implicated in severe outbreaks. No vaccine is currently available for this disease.

The clinical course of EHD in wild and captive deer is usually rapid, with disease onset approximately seven days after infection. Clinical signs include ptyalism, submandibular swelling, dyspnea, anorexia, or neurological signs. Many deer are simply found dead. Classically, deer found dead near a body of water were thought to have died of EHD as the disease induces body temperatures of up to 106° F. The gross lesions, which typically include petechiae and ecchymoses in multiple tissues, result from systemic vasculitis. Infarcts, with areas of ulceration and necrosis, result from thrombosis of affected vessels. Common locations for infarcts, with subsequent ulceration, include the tongue, oral mucosa, gingival, esophagus, and forestomachs. Commonly, pulmonary edema and fibrinous pleuritis are the only gross lesions observed, both the results of increased vascular permeability.

During the summer of 2007, the Purdue ADDL and Heeke ADDL diagnosed 12 cases of EHD, with 11 positive cases by either FA or virus isolation and 1 suspected case based on gross lesions. Of the 12 total cases, 11 were from White-tailed deer and 1 case was from a beef cow. Cases occurred from August through October. In most cases, numerous deer were affected or found dead, making the actual number of infected deer in Indiana greater than the case load suggests. Submissions came from various locations in both the northern and southern portions of Indiana, and were submitted by deer farmers,

veterinarians, hunters, and DNR personnel. Based on ADDL records, the summer of 2007 saw the most confirmed cases of EHD in recent years. When late summer arrives in Indiana, those veterinarians who serve farmed deer should consider EHD as an important differential diagnosis when confronted with seriously ill or dead deer.
-by Dr. Grant Burcham, ADDL Graduate Student

References:

1. Brown CC, Baker DC, Barker IL: 2007. Alimentary system. IN: Jubb, Kennedy and Palmer's Pathology of Domestic Animals, ed. Maxie MG, 5th ed., Vol 2, pp 201-203.
2. House C, Shipman LD, Weybright G: 1998. Serological diagnosis of Epizootic Hemorrhagic Disease in cattle in the USA with lesions suggestive of vesicular disease. Annals NY Academy of Sciences. June 29. 849:497-500.
3. Radostits OM, Gay CC, Hinchcliff KW, Constable PD: 2007. Diseases associated with viruses and *Chlamydia*. In: Veterinary Medicine: A textbook of the diseases of cattle, horses, sheep, pigs, and goats. Elsevier Saunders, Philadelphia, PA.10th ed., p 1305
4. Stallknecht DE et al: 1995. Epizootic Hemorrhagic Disease virus and Bluetongue virus serotype distribution in White-tailed deer in Georgia. Journal of Wildlife Disease 31(3): 331-338.
5. Trainer DO: 1964. Epizootic Hemorrhagic Disease of Deer. Journal of Wildlife Management. 28 (2)

ADDL test results are available on the Internet. Log on to ADDL website www.addl.purdue.edu, Click on Online Rpts tab, then Request Info., or call 765-494-7440 to set up an account.

Purdue ADDL and Heeke ADDL will be closed on the following University holidays in 2008.

May 26.....Memorial Day
 July 4.....Independence Day
 September 1.....Labor Day
 November 26-27.....Thanksgiving

Hepatic Lipidosis in Toy Breed Dogs



Hepatic lipidosis, or fatty liver, is the condition of triglyceride accumulation in the liver which can be either physiologic or pathologic. Hepatic lipidosis can occur due to alterations in any point of normal lipid

metabolism, including increased delivery of fatty acids to the liver, decreased use or oxidation of fatty acids, preferential esterification of triglycerides, choline or methionine deficiency resulting in decreased phospholipid synthesis, or decreased lipoprotein secretion.

In domestic animals, hepatic lipidosis most commonly occurs in cats, cows, and horses, and is usually associated with fasting or anorexia. However, increased energy demand, especially during pregnancy or lactation, diabetes mellitus, nutritional deficiencies such as choline deficiency, or hepatocellular injury can also result in hepatic lipidosis.

In dogs, hepatic lipidosis primarily occurs in young, toy-breed dogs, with Yorkshire terriers, Chihuahuas, and Fox terriers appearing to be the most susceptible. Hepatic lipidosis in young dogs is often preceded by a period of anorexia with subsequent development of hypoglycemia. Periods of anorexia are usually associated with incidences of stress, such as transfer of ownership, vaccination, weaning, tattooing, or surgery. Young, especially toy breed, dogs are at increased risk of developing hypoglycemia because their disproportionately small muscle mass and limited hepatic glyconeogenesis capacity cannot sustain their high basal metabolic energy requirements. Large breed pups and adult dogs appear to be inherently more resistant to fasting hypoglycemia. Since adults have more developed glycohomeostatic mechanisms, they maintain normal glucagon levels, and only experience mild decreases in insulin initially which will rise slightly with prolonged fasting. In one retrospective study, the majority of pups with hepatic lipidosis presented with neurologic signs, including muscle weakness, ataxia, somnolence, convulsions, opisthotonus, and coma. These neurologic signs were attributed to cerebral neuronal necrosis due to hypoglycemia. Neurologic signs were often preceded by vomiting and diarrhea. Additionally, 40% of dogs with hepatic lipidosis had lymphoid depletion and thymic atrophy.

In experimentally fasted Yorkshire terrier pups, inadequate glyconeogenesis and hypoglycemia resulted in hypoinsulinemia, hyperglucagonemia, and ketogenesis with blood glucose levels rapidly declining when dogs were fasted more than 16 hours. Interestingly, within only eight hours of fasting, blood glucose rose above the normal values for an adult (3.9—5.0 mM/l) to more than 7.0mM/l before falling drastically below 1.0 mM/l with continued fasting. Additionally, ketone body production coincided with decreasing glucose levels.

On gross examination, puppies with hepatic lipidosis have moderately enlarged, diffusely pale yellow liver. In some cases, livers will float in formalin. Histologically, hepatocytes have diffuse microvesicular vacuolation. In a retrospective study, liver fat content with hepatic lipidosis ranged from 32-54% dry weight, as compared to a control pup that had 2% dry weight fat content.

Like cats with hepatic lipidosis, it may be beneficial to feed toy breed pups and bitches a protein-rich diet, frequently to prevent fatty liver from occurring. Such a diet may also aid in recovery from an episode of anorexia-induced hepatic lipidosis.


-by Lisa Bartner, Michigan State University SVM Extern
-edited by Dr. Joshua Webster, ADDL Graduate Student

References:

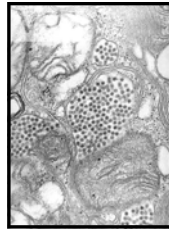
- 1 Kelly RW: 1993. The liver and biliary system in: Pathology of Domestic Animals, 4th ed., Jubb KVF, Kennedy PC, Palmer N, eds. Academic Press, Boston, pp. 319-406.
- 2 King NW, Alroy J: 1997. Intracellular and extra-cellular depositions, degenerations. In: Veterinary Pathology, 6th ed. Jones TC, Hunt RD, King NW, eds..
- 3 Linde-Sipman JSvd, Ingh TSGAMvd et al: 1990. Fatty liver syndrome in puppies. JAAHA 26:9-12.
- 4 Toor AJv, Linde-Sipman JSvd, Ingh TSGAMvd 35 al: 1991. Experimental induction of fasting hypoglycemia and fatty liver syndrome in three Yorkshire pups. Vet Quarterly 13: 16-23.



**Winter at Heeke
ADDL, Dubois, IN**




Eastern Equine Encephalitis



Eastern equine encephalomyelitis (EEE) is an arthropod-borne disease belonging to the genus *Alphavirus*. It causes severe and sometimes fatal encephalitis in game birds and various mammalian species (e.g. horses and humans). The disease was first recognized in 1831 when 75 horses died of an encephalitic condition in Massachusetts. The EEE virus was isolated in 1933 when a major outbreak of encephalomyelitis occurred in horses in the coastal areas of Delaware, Maryland, New Jersey, and Virginia.

Eastern equine encephalomyelitis is a single-stranded, enveloped RNA virus in the family *Togaviridae*. The genus *Alphavirus* contains two other viruses, Western equine encephalomyelitis (WEE) and Venezuelan equine encephalomyelitis (VEE), which are closely related to EEE. Eastern equine encephalomyelitis is endemic in Central America, the eastern part of South America, the Caribbean, and regions of North America. Two antigenic variants of EEE are recognized and are geographically categorized. The more virulent North American variant is found in the eastern United States, Canada, and the Caribbean and seems more likely to infect humans. The South American variant is found in South and Central America. In the United States, EEE is most prevalent in the Atlantic and Gulf Coast states, but occasional outbreaks have been identified in Texas, Minnesota, and South Dakota, as well as in most states east of the Mississippi River. In the northern regions of the United States, EEE cases occur in the late summer to early fall in and around lowland swamp areas.

Small species of passerine birds are the principal vertebrate reservoir for EEE. They rarely become ill with the disease but serve to maintain and amplify the virus. The enzootic vector responsible for transmitting the virus among passerine, poultry, and game birds is the *Culiseta melanura* mosquito. This species of mosquitoes is ornithophilic, so it is less likely to play a role in the transmission to horses and humans. The epizootic mosquito vectors, or bridging vectors are believed to be *Coquillettidia* spp. and *Aedes* spp. These species of mosquitoes pick up the virus from infected birds and then infect mammals. Horses and humans are regarded as accidental or dead end hosts because they do not develop a sufficiently high viremia to re-infect mosquitoes and maintain the transmission cycle.



After initial infection with EEE, the virus replicates in myocytes, fibroblasts, reticuloendothelial cells, lymphoid cells and osteoblasts. One study found that

active osteoblasts may be one of the main sites of virus amplification. This could explain why young animals are more susceptible to serious infection and develop higher levels of viremia. Following initial amplification, there is a primary viremia, and replication occurs in other extraneuronal tissues (e.g. lymph nodes and muscles) prior to the second viremic phase. Eventually, through a hematogenous route, EEE is thought to enter the central nervous system (CNS). Once in the CNS, viral replication is believed to occur in neurons, vascular endothelial cells, and glial cells. Eastern equine encephalomyelitis is thought to induce damage by stimulating apoptosis of neuronal and glial cells. The incubation period of EEE is 4-10 days. The initial clinical signs of EEE in affected horses can include any of the following: biphasic fever, anorexia, somnolence, head pressing, stiff neck, and proprioceptive deficits. These signs can progress rapidly to cortical blindness, circling, head tilt, nystagmus, strabismus, paralysis, seizures, and possibly death. Some horses show no clinical signs before dying. The case fatality rate is 50-90% in horses and 30-50% in humans. Animals that recover commonly have mild to moderate long-term neurological dysfunction.

The clinical signs of EEE are indistinguishable from WEE, VEE, and other encephalitides, such as rabies, leukoencephalomyelitis, equine herpes virus 1, equine protozoal myeloencephalitis, and West Nile virus. Therefore, additional antemortem or postmortem tests are required for a definitive diagnosis. The antemortem diagnosis is based on detection of a single serum high titer or an elevation in paired titers. It can be difficult to get paired titers because horses commonly will not live long enough to be able to get a second serum sample. Detection of IgM in the early stage of infection is made by antigen capturing ELISA. In addition, there are other serological tests available such as hemagglutination inhibition, complement fixation, and virus neutralization assay. A definitive diagnosis often is made postmortem with immunohistochemistry, virus isolation, or reverse transcription polymerase chain reaction (RT-PCR) on nervous tissues.

Usually, no gross lesions are seen in the brain or spinal cord at necropsy; however, occasionally, hyperemia, congestion, and focal areas of hemorrhage are found in the gray matter. A characteristic change to differentiate EEE from other encephalitides is diffuse lymphocytic/neutrophilic perivascular cuffing and infiltration of the gray matter of the cerebral cortex, the thalamus, and hypothalamus. Eastern equine encephalomyelitis infected animals can die so acutely that neutrophils are still the predominant inflammatory cell type. The cerebellum is often affected less severely, and only mild changes are observed in the gray matter of the spinal cord. Less definitive findings are endothelial cells swelling with prominent hyaline thrombi, perivascular hemorrhage and edema, diffuse microgliosis, cortical necrosis, and neuronal degeneration.

There is no specific treatment for EEE. Treatment is generally focused on supportive care, which includes providing padding to protect animals from self-induced trauma, anti-inflammatory drugs to limit the secondary inflammation, fluids and electrolytes. More important is prevention of EEE infection. There are several inactivated monovalent, bivalent (EEE, WEE) and trivalent (EEE, WEE, VEE) vaccines available. It is recommended to give three vaccinations to unvaccinated horses and foals 4-6 weeks apart. Then give a booster vaccination annually prior to peak mosquito season. A booster vaccination can be given to mares 4-6 weeks prior to foaling to increase the concentration of antibodies in their colostrum. Foals should be given their first vaccination at approximately 6 months of age or, if the mare was unvaccinated, at 3-4 months of age.

Controlling vectors, elimination of breeding sites and control of mature insects will increase the success of preventive measures, particularly during outbreaks of disease. Horses may be partially protected from insects if repellent is used.

In late summer and early fall of 2007, several horses in Indiana were diagnosed with EEE infections. Initial diagnosis was made at Purdue ADDL and later confirmed at NVSL by PCR and/or VN, IgM capturing ELISA. No human fatality has been recorded due to EEE virus infection in Indiana.

-by Chad Frank, Michigan State University SVM Extern
-edited by Dr. Roman Pogranichniy, ADDL Virologist

References:

1. Animal and Plant Health Inspection Service web site. Eastern Equine Encephalomyelitis. Available at: www.aphis.usda.gov/pa/pubs/fsheet_faq_notice/fs_aheasterne.htm. Accessed September 23, 2007.
2. Murphy AF., Gibbs PJ, Horzinek MC et al: 1999. Flaviviridae. *Veterinary Virology* 3rd ed. San Diego CA: Academic Press. Pp 550--553.
3. Calisher CH: 1994. Medically Important Arboviruses of the United States and Canada. *Clinical Microbiology Reviews*: 89-116.
4. Brault AC, Powers AM, Chavez CL et al: 1999. Genetic and Antigenic Diversity Among Eastern Equine Encephalitis Virus from North, Central, and South America. *American Journal of Tropical Medicine and Hygiene*. 61: 579-586.
5. Saif YM: 2003. Other Viral Infections. *Diseases of Poultry*, 11th ed. Ames, IA: Iowa State Press. Pp 388-392.
6. Vogel P, Kell WM, Fritz EL et al: 2005. Early Events in the Pathogenesis of Eastern Equine Encephalitis Virus in Mice. *American Journal of Pathology*. 166: 159-171.
7. Jubb KFV, Kennedy, Palmer N: 1993. Inflammation of the Central Nervous System. *Pathology of Domestic Animals*, 4th ed. San Diego CA: Academic Press. Pp 412-414.
8. Smith BP: 2002. Nervous System. *Merck Veterinary Manual*, 9th ed. Whitehouse Station NJ: Merck & Co., Inc. Pp 1031-1032.

9. Kahn CM: 2002. Nervous System. Merck Veterinary Manual. 9th ed. Whitehouse Station, NJ: Merck & Co., Inc. Pp 1031-1032.
10. Piero FD, Wilkins PA, Dubovi EJ et al: 2001. Clinical, Pathological, Immunohistochemical, and Virological Findings of Eastern Equine Encephalomyelitis in Two Horses. Veterinary Pathology 38: 451-456.

ADDL NEWS



Dr. Ching Ching Wu, ADDL's Chief of Microbiology and Avian Laboratory Services was invited to represent Purdue University and the American Veterinary Medical Association at the Codex Intergovernmental Task Force on Antimicrobial Resistance held in Seoul, Korea, October, 2007.

Drs. Leon Thacker, Roman Pogranichniy, Duane Murphy, Jose Ramos-Vara, Steve Hooser, Ching Ching Wu, Tsang Long Lin, Joshua Webster and Steve Vollmer and Buffie Mink attended the annual American Association of Veterinary Laboratory Diagnosticians annual meeting in Reno, NV, October, 2007.

Histology Laboratory Supervisor **Paula Brost** and technician **Charlene Evans** recently passed the National Society for Histology board examination and are now certified by the American College for Clinical Pathology.

Our congratulations to ADDL graduate students **Drs. Pam Mouser and Robert Johnson** for receiving Young Investigator Awards at the recent American College of Veterinary Pathologists meeting in Savannah, Georgia. Dr. Mouser was awarded second place in the category of Natural Diseases for her poster "Spontaneous canine intraepithelial mammary gland lesions as a model for human breast preneoplasia". Dr. Johnson received the second place award in the category of Diagnostic Pathology for his presentation "Genomic Identification of *Bartonella henselae* in an Aborted Equine Fetus"

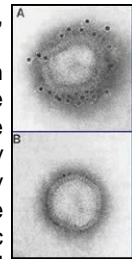
Swine Influenza



Influenza virus infections are not only an important and common cause of respiratory disease to pigs across the world, but also pose important human public health concerns. Swine influenza virus first appeared in western Illinois in 1918, where it caused not only an epizootic outbreak in swine, but also a pandemic in humans. There is definitive evidence that influenza virus can spread between species including swine, chickens, ducks, turkeys, wild birds, and humans. With the recent interest in avian influenza, it is important to understand that pigs can be "mixing vessels" for the various strains of influenza because they are susceptible to infection with both human and avian influenza A viruses. Their ability to become co-infected with various strains can lead to genetic reassortment of the virus and several different types of viral reassortments have been isolated from pigs around the world, especially from China and the Far East. This poses an important public health concern since swine could serve as a host to create novel mammalian influenza viruses that could lead to a pandemic outbreak in humans. This article will discuss the important features of swine influenza virus, including etiology, epidemiology, clinical signs, lesions, diagnosis, and prevention.

Swine influenza is an influenza A virus in the family Orthomyxoviridae. They are pleomorphic enveloped viruses. Since the virus has a lipid envelope, it is very susceptible to detergents and many common antiviral disinfectants. The influenza virus can easily undergo genetic reassortment due to their segmented genome. Influenza viruses are named based on the major surface antigens. There are 13 hemagglutinins (H) and 9 neuraminidase (N). The two major subtypes affecting pigs in the U.S. are H1N1 and H3N2. H1N1 is the classic subtype in swine and has been the predominant strain in the U.S. since 1918. The emergence of H3N2 occurred in 1997 and is now commonly isolated as well.

In the United States today, swine influenza is common and widespread, with serologic surveys of the Midwest revealing that nearly all herds have antibodies to the virus. Swine influenza can occur in all ages of swine. Historically, acute seasonal outbreaks in the fall and early winter months were most commonly recognized. Today, due to an increase in confinement operations, endemic swine flu causes continuous low levels of disease year round in many swine herds. Influenza virus is most commonly transmitted through pig-to-pig nasal contact since the virus is shed in nasal secretions. Also, the virus can be introduced into a herd during movement of new animals.



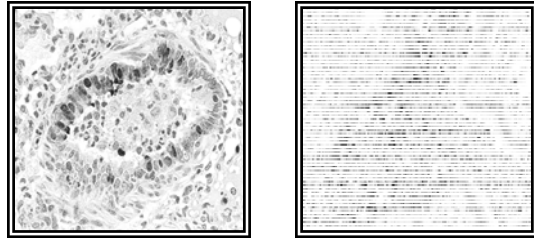
The incubation period for swine influenza virus ranges from 1-3 days, with viral shedding as early as 1 day post infection and ceasing within 7 days. Even though swine influenza is an acute infection and cleared rapidly, clinical illness can persist for weeks in a herd, while the virus is being transmitted from pig to pig. The severity and course of infection depends on co-infection with other agents, age, and overall immune status. The virus usually replicates in the nasal epithelium, lungs, trachea, tonsils, and tracheo-bronchial lymph nodes, most commonly limiting the viral infection to the respiratory tract. The viral attachment and replication in the nasal and tracheal epithelium damages the mucociliary apparatus which allows the infection to spread to the lungs. This can then predispose the pig to secondary bacterial infections in the lung.

The diagnosis can be made presumptively based on clinical signs. The clinical signs of a typical outbreak include pyrexia, anorexia, lethargy, prostration, huddling, and reluctance to move. Nasal and ocular discharge may also be observed. A characteristic dry, hacking "goose honk" cough may also be heard and is associated with the animals being forced to move. The disease may progress to open mouth labored breathing. In uncomplicated swine influenza infections, there is high morbidity and low mortality, causing loss of body condition, weight loss, and delays in marketing (about 1 week). Recovery begins about the 6th day post infection and the herd is generally recovered in a week or two. If clinical cases of swine influenza become complicated with other pathogens such as *Actinobacillus pleuropneumonia*, *Pasteurella multocida*, *Mycoplasma hyuopneumoniae*, or *Streptococcus suis*, this can increase mortality or prolong recovery time. Subclinical infections do occur in finishing pigs. Reproductive problems, such as abortion or small, weak litters, have been associated with acute illness in swine influenza in sows.

Gross lesions associated with uncomplicated swine influenza are typical of viral pneumonia. The lungs are red, wet and heavy. The lesions are often more severe in the apical and cardiac lung lobes, and typically include a patchy or checkerboard pattern of distinct purple collapsed lobules (bronchointerstitial pneumonia). Some blood tinged fibrinous exudate may also be observed in the airways, and the associated bronchial and mediastinal lymph nodes may be enlarged.

The common histopathologic lesion of swine influenza infection is attenuation, necrosis, and desquamation of the bronchial and bronchiolar epithelium. The airway lumens are often plugged with neutrophils, monocytes, and necrotic epithelial cells. Alveolar septae are thickened with lymphocyte, macrophage, and plasma cell infiltrates, and may have type-2 pneumocyte hyperplasia. There is also peribronchial and perivascular cuffing by lymphocytes.

Definitive diagnosis is based on virus isolation from a swab of nasal mucosa or pharynx, for very young pigs. The swab should be made of polyester, not cotton, and should be kept cold during transport. The virus is best isolated from the nasal and pharyngeal secretions when the animals are febrile. Diagnosis can also be done by immunohistochemistry (IHC, Fig. 1&2)



Figures 1&2: IHC images are representative of immunostaining of the viral antigen, which is present in the cytoplasm and/or nucleus of the bronchiolar epithelium. Photos are courtesy of Dr. Jose Ramos-Vara

Since there are no specific treatments for swine influenza infections, prevention and control are very important. Treatment of clinically ill animals can include anti-inflammatories to offer some relief for the severely affected, antimicrobials to prevent secondary bacterial infections and, most importantly, clean fresh water, good management and environment. Prevention is largely dependent on biosecurity and avoiding the introduction of carrier animals. New animals to be introduced into the herd can be vaccinated while in isolation and acclimation. Inactivated swine influenza vaccines are commercially available. All ages of swine may be vaccinated and immunity lasts about three months. Colostral immunity will interfere with vaccination in pigs <10-13 weeks old. Influenza control in nursing pigs can be achieved by vaccinating the sow five and two weeks pre-farrowing, which will increase maternal antibody levels. Successful control of swine influenza in the grower/finisher phase of swine influenza positive herds can be challenging. To control influenza during this phase, pigs can be vaccinated at ten weeks of age, and then again two weeks later.

-by Angie Delks, PUSVM Class of 2008

-edited by Dr. Duane Murphy, Heeke ADDL

References:

1. Amass, Sandra. VCS 510. Swine Medicine class notes. Fall 2005-2006.
2. Cos NJ and Subbarao K: 2000. Global Epidemiology of Influenza: Past and Present. Annual Review of Medicine. 51: 407-421.
3. Schwartz KJ: 2004. Swine Disease Manual, 4th ed. American Association of Swine Veterinarians.
4. Straw B et al (eds): 2006. Diseases of Swine, 9th ed. Blackwell Publishing, Ames, IA.

Percent resistance to antimicrobials from selected animal pathogens--data supplied by Bacteriology Section, ADDL, Purdue University
(periods of Jan-Jun and Jul-Dec, 2007)

| Antimicrobials | Canine | | Equine | | Feline | |
|--------------------------------|------------|------------|-----------|-----------|-----------|-----------|
| | Jan.-June | July-Dec. | Jan.-June | July-Dec. | Jan.-June | July-Dec. |
| E. Coli | 3 | 3 | 5 | 3 | 0 | 0 |
| | 58 | 74 | 3 | 0 | 0 | 0 |
| Enterococcus sp. | 32 | 28 | 0 | 0 | 0 | 0 |
| | 100 | 100 | 0 | 0 | 0 | 0 |
| Pse. aeruginosa | 7 | 5 | 50 | 50 | 3 | 7 |
| | 100 | 100 | 0 | 0 | 24 | 0 |
| Staph. aureus | 63 | 64 | 100 | 100 | 35 | 33 |
| | 0 | 0 | 0 | 0 | 0 | 0 |
| Staph. intermedius | 0 | 0 | 0 | 0 | 0 | 0 |
| | 50 | 25 | 0 | 0 | 24 | 0 |
| E. Coli | 11 | 3 | 3 | 0 | 24 | 0 |
| | 11 | 3 | 0 | 0 | 0 | 0 |
| Salmonella sp. | 0 | 0 | 0 | 0 | 0 | 0 |
| | 50 | 50 | 0 | 0 | 0 | 0 |
| Staph. aureus | 0 | 0 | 100 | 100 | 35 | 33 |
| | 0 | 0 | 0 | 0 | 0 | 0 |
| Staph. epidermidis | 0 | 0 | 0 | 0 | 0 | 0 |
| | 38 | 48 | 0 | 38 | 48 | 33 |
| Strep. equi | 0 | 0 | 0 | 0 | 10 | 13 |
| | 100 | 100 | 0 | 0 | 0 | 0 |
| Strep. zooepidemicus | 0 | 0 | 0 | 0 | 0 | 0 |
| | 60 | 60 | 0 | 0 | 6 | 6 |
| E. Coli | 14 | 22 | 0 | 0 | 0 | 0 |
| | 14 | 22 | 0 | 0 | 0 | 0 |
| Enterococcus sp. | 0 | 0 | 0 | 0 | 0 | 0 |
| | 57 | 57 | 0 | 0 | 0 | 0 |
| Pse. aeruginosa | 0 | 0 | 0 | 0 | 0 | 0 |
| | 100 | 100 | 0 | 0 | 0 | 0 |
| Staph. aureus | 0 | 0 | 0 | 0 | 0 | 0 |
| | 67 | 67 | 0 | 0 | 0 | 0 |
| Amikacin | 3 | 3 | 5 | 3 | 0 | 0 |
| Amoxyicillin/Clavulanic acid | 29 | 23 | 11 | 3 | 14 | 22 |
| Ampicillin | 55 | 52 | 25 | 35 | 29 | 44 |
| Cefazolin | 33 | 33 | 14 | 3 | 7 | 22 |
| Cefoxitin | 32 | 29 | 11 | 3 | 7 | 22 |
| Cefpodoxime | 27 | 30 | 14 | 3 | 7 | 22 |
| Ceftiofur | 26 | 26 | 9 | 3 | 7 | 22 |
| Cephalothin | 39 | 36 | 16 | 3 | 7 | 22 |
| Chloramphenicol | 16 | 18 | 11 | 17 | 14 | 11 |
| Clindamycin | 100 | 100 | 100 | 100 | 100 | 100 |
| Enrofloxacin | 27 | 27 | 7 | 10 | 7 | 22 |
| Erythromycin | 100 | 100 | 100 | 100 | 100 | 100 |
| Gentamicin | 23 | 20 | 18 | 14 | 7 | 22 |
| Imipenem | 0 | 0 | 0 | 0 | 0 | 0 |
| Marbofloxacin | 27 | 28 | 7 | 10 | 7 | 22 |
| Orbitofloxacin | 27 | 28 | nt | nt | 7 | 22 |
| Oxacillin + 2% NaCl | 99 | 99 | 100 | 100 | 93 | 100 |
| Penicillin | 100 | 100 | 100 | 100 | 100 | 100 |
| Rifampin | 96 | 93 | 98 | 90 | 86 | 83 |
| Tetracycline | 38 | 41 | 23 | 38 | 14 | 33 |
| Ticarcillin | 52 | 47 | 23 | 35 | 29 | 44 |
| Ticarcillin/Clavulanic Acid | 23 | 14 | 2 | 3 | 7 | 22 |
| Trimethoprim/Sulphamethoxazole | 36 | 31 | 34 | 52 | 14 | 28 |
| number of isolates | 128 | 160 | 44 | 29 | 14 | 18 |

nt - not tested

Percent resistance to antimicrobials from selected animal pathogens --data supplied by Bacteriology Section, ADDL, Purdue University
(periods of Jan-Jun and Jul-Dec, 2007)

| Antimicrobials | Canine | | | | | | Equine | | | | | | Feline | | | | | | | | | | | | | | |
|--------------------|-----------|-----------|-----------|-----------|-----------|-----------|-----------|-----------|-----------|-----------|-----------|-----------|-----------|-----------|-----------|-----------|-----|-----|-----|-----|-----|-----|-----|-----|-----|----|----|
| | Jan.-June | July-Dec. | Jan.-June | July-Dec. | Jan.-June | July-Dec. | Jan.-June | July-Dec. | Jan.-June | July-Dec. | Jan.-June | July-Dec. | Jan.-June | July-Dec. | Jan.-June | July-Dec. | | | | | | | | | | | |
| E. coli | 44 | 47 | 0 | 0 | 0 | 50 | 100 | 0 | 59 | 60 | 50 | 0 | 20 | 33 | 66 | nt | 29 | 62 | 2 | 0 | 56 | 76 | 60 | 61 | 6 | 3 | |
| | 15 | 20 | 0 | 0 | 17 | 0 | 100 | 0 | 43 | 32 | 0 | 100 | 0 | 0 | 0 | nt | 29 | 46 | 2 | 0 | 22 | 34 | 40 | 44 | 4 | 4 | |
| | 65 | 86 | 0 | 0 | 17 | 0 | 100 | 0 | 79 | 83 | 0 | 0 | 0 | 100 | nt | 29 | 65 | 5 | 10 | 76 | 95 | 73 | 74 | 86 | 92 | | |
| | 100 | 100 | 100 | 100 | 100 | 100 | 100 | 100 | 100 | 100 | 0 | 0 | 100 | 20 | nt | nt | 100 | 100 | 38 | 10 | 100 | 100 | 100 | 100 | 88 | 90 | |
| | 8 | 14 | 0 | 0 | 17 | 0 | 100 | 0 | 14 | 19 | 0 | 0 | 0 | 100 | nt | nt | 0 | 4 | 20 | 5 | 0 | 1 | 0 | 0 | 5 | 1 | |
| | 47 | 57 | 50 | 0 | 17 | 0 | 100 | 0 | 62 | 62 | 0 | 0 | 0 | 0 | nt | nt | 29 | 58 | 4 | 0 | 47 | 63 | 40 | 57 | 2 | 0 | |
| | 12 | 21 | 0 | 0 | 33 | 0 | 100 | 0 | 36 | 46 | 75 | 0 | 0 | 20 | nt | nt | 7 | 15 | 4 | 15 | 12 | 13 | 0 | 9 | 7 | 6 | |
| | 18 | 29 | 50 | 0 | 17 | 50 | 100 | 0 | 61 | 75 | 75 | 0 | 60 | 100 | nt | nt | 7 | 54 | 0 | 45 | 38 | 52 | 7 | 4 | 25 | 31 | |
| | 71 | 86 | 50 | 100 | 33 | 50 | 100 | 0 | 86 | 85 | 25 | 0 | 60 | 80 | nt | nt | 29 | 69 | 21 | 35 | 77 | 97 | 73 | 83 | 95 | 94 | |
| | 100 | 100 | 0 | 0 | 100 | 100 | 100 | 100 | 100 | 100 | 50 | 0 | 100 | 100 | 100 | 100 | 100 | 100 | 100 | 100 | 100 | 100 | 100 | 100 | 100 | 18 | 24 |
| | 35 | 36 | 0 | 0 | 50 | 0 | 100 | 25 | 69 | 73 | 100 | 0 | 40 | 40 | nt | nt | 64 | 42 | 23 | 30 | 61 | 54 | 100 | 78 | 24 | 13 | |
| | 60 | 60 | 50 | 0 | 50 | 100 | 100 | 75 | 63 | 59 | 25 | 0 | 4 | 67 | 50 | 100 | 93 | 92 | 18 | 20 | 69 | 80 | 93 | 83 | 69 | 73 | |
| | 90 | 93 | 0 | 0 | 0 | 0 | 100 | 100 | 97 | 96 | 0 | 0 | 0 | 20 | nt | nt | 100 | 100 | 0 | 0 | 99 | 97 | 100 | 100 | 14 | 23 | |
| | 100 | 100 | 50 | 0 | 50 | 50 | 100 | 100 | 100 | 100 | 0 | 0 | 20 | 80 | nt | nt | 100 | 100 | 7 | 5 | 100 | 100 | 100 | 100 | 89 | 84 | |
| | 22 | 36 | 0 | 0 | 0 | 0 | 100 | 0 | 51 | 65 | 0 | 0 | 0 | 20 | nt | nt | 14 | 31 | 4 | 5 | 20 | 21 | 13 | 9 | 5 | 1 | |
| | 100 | nt | 100 | nt | 75 | nt | 100 | nt | 100 | nt | 100 | 100 | 100 | nt | nt | nt | 100 | nt | 67 | nt | 100 | nt | 100 | nt | 91 | nt | |
| number of isolates | 11 | 15 | 2 | 1 | 6 | 2 | 1 | 4 | 87 | 52 | 4 | 1 | 5 | 10 | 12 | 8 | 14 | 26 | 56 | 20 | 131 | 101 | 15 | 23 | 84 | 71 | |

nt - not tested

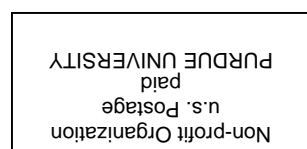
DIAGNOSTIC FORUM

DIAGNOSTIC FORUM is a quarterly newsletter of current services, regulations and research projects involving the ADDL which may be of interest to Indiana veterinarians and animal owners. It is our intention that the information provided will serve you. To know how successful we are, we would like to hear from you. Please send your comments, suggestions, requests and questions to: Diagnostic Forum Editor, Animal Disease Diagnostic Laboratory, 406 S. University, Purdue University, West Lafayette, IN 47907-1175.

ADDL SECTION HEADS AND PATHOLOGISTS

| | |
|--|--|
| Director: H.L. Thacker, DVM, PhD | Histology: Jose Ramos-Vara, DVM, PhD |
| Assistant Director: Steve Hooser, DVM, PhD | Pathology: Greg Stevenson, DVM, PhD |
| Assistant to Director: Linda Hendrickson, BS, MA | Molecular Diagnostics: R. Vemulapalli, DVM, PhD |
| Avian: Tsang Long Lin, DVM, PhD | Serology: Roman Pogranichniy, DVM, PhD |
| Bacteriology: Ching Ching Wu, DVM, PhD | Toxicology: Stephen Hooser, DVM, PhD |
| Business Office: Tonya Byrd | Virology: Roman Pogranichniy, DVM, PhD |
| Computer: Steve Vollmer, BS | Heeke ADDL: Tom Bryan, DVM Duane Murphy, DVM, PhD |

Veterinary Pathologists: Christine Hanika-Holland, DVM, PhD
Tsang Long Lin, DVM, PhD
Peg Miller, DVM, PhD
Greg Stevenson, DVM, PhD
Leon Thacker, DVM, PhD
Bill Van Alstine, DVM, PhD
Jose Ramos-Vara, DVM, PhD



ANIMAL DISEASE DIAGNOSTIC LABORATORY
PURDUE UNIVERSITY
406 S. UNIVERSITY ST
WEST LAFAYETTE, IN 47907