

Diagnostic Forum

A Quarterly Newsletter from the Indiana Animal Disease Diagnostic Laboratory at Purdue University

Inside the Forum

V O L 2 2 N O 1

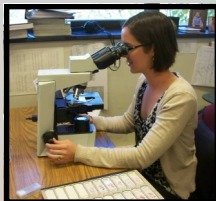W I N T E R 2 0 1 2

From the Director	P. 1
Equine Piroplasmosis	P. 1
Chicken Jerky Treats Warning	P. 2
BVD in White-Tailed Deer in Indiana	P. 2
Mast Cell Tumors Revisited	P. 3
ADDL Schedule	P. 4

Our congratulations to former ADDL graduate students, Drs. Abby Durkes, Chad Frank and Ryan Jennings who recently became Diplomates of the American College of Veterinary Pathologists by successfully completing the certifying Board Examination.



Dr. Frank



Dr. Durkes



Dr. Jennings

From the Director

Stephen B Hooser

Equine Piroplasmosis Testing

The Indiana Animal Disease Diagnostic Laboratory is pleased to announce that it has been approved to perform Equine Piroplasmosis testing for inter- and intrastate movement and began offering the tests for Equine Piroplasmosis January 1, 2012.

To be eligible for a waiver of the test fee for state mandated testing, serum samples submitted for Equine Piroplasmosis must state on the ADDL accession form that the samples are from horses currently belonging to Indiana owners and will be at the Indiana race tracks: Hoosier Park, Anderson, IN and Indiana Downs, Shelbyville, IN. Samples submitted to ADDL for testing must be drawn by a licensed and accredited veterinarian, the animal ID must be listed, and the reason for testing must be clearly stated on the ADDL submission form.

Testing for international export or for cases with clinical signs compatible with Equine Piroplasmosis must be tested at the USDA National Veterinary Services Laboratory.

The charge for non-state mandated Equine Piroplasmosis testing for both *B. caballi* and *T. equi* will be \$24 (\$7 each for *B. caballi* and *T. equi*, plus the \$10 ADDL accession fee).

Changes to CWD Program

Due to changes in the federal CSD surveillance program, the ADDL will begin charging for CWD testing for captive cervids beginning January 1, 2012. Please see the ADDL website for details.



Equine Piroplasmosis

By Dr. Grant Minnemeyer (Class of 2011) and Rachel Beetz (Class of 2012)
 Edited by Drs. Abby Durkes, ADDL Graduate Student, and Peg Miller, ADDL Pathologist

Abstract:: Equine piroplasmosis (EP) is caused by a protozoal infection of erythrocytes. The causative agents are *Theileria equi* and *Babesia caballi*. EP is transmitted by ticks and contaminated blood sources. Clinical signs of the disease vary from asymptomatic to hemolytic anemia and numerous additional signs that mimic other equine diseases. Diagnosis is based on blood smears and serological testing. Treatment options are available to alleviate the clinical signs; however, in the United States, EP is both a foreign animal disease and a reportable disease, so treatment of infected horses is controlled by the USDA.

EP is a major concern in transportation of equids, especially internationally. Prevention and control is focused on tick control and strict importation and isolation protocols. The United States is not considered an endemic area. EP has been a popular topic in the equine industry due to the recent outbreak in the U.S., as well as in Lexington, KY in 2010, where many horses were imported internationally, including from endemic areas, to compete at the World Equestrian Games (WEG).

The entire article and references can be found on our website < www.addl.purdue.edu > or faxed/mailed to you upon request.



Chicken Jerky Treats Associated with Illness in Dogs

By Dr. Christina Wilson and Kimberly Meyerholtz

The U.S. Food and Drug Administration (FDA) has issued a cautionary warning to pet owners regarding concerns that imported chicken jerky products may be associated with illness in dogs. The chicken jerky products in question include those sold as chicken tenders, chicken strips or treats. The clinical signs observed in affected dogs can occur within hours to days after feeding these products and may include anorexia, dehydration, vomiting/diarrhea (sometimes with blood), weakness, polydipsia, and/or polyuria. Serum biochemistries and venous blood gas analyses may reveal elevated BUN or creatinine, hyponatremia, hypokalemia, and/or metabolic acidosis. Urinalysis may indicate an acquired form of Fanconi syndrome as supported by glucosuria (with normoglycemia or

hypoglycemia), ketonuria, and proteinuria/aminoaciduria in the affected dog.

The FDA is advising pet owners who feed their dogs chicken jerky products to stop feeding the product if any of the aforementioned clinical signs are observed in their pet. In suspect cases, veterinarians should report illnesses associated with chicken jerky products to the FDA Consumer Complaint Coordinator in Indiana by telephone at (313) 393-8189 or access the online FDA pet food complaint portal at

<http://www.fda.gov/petfoodcomplaints>.

The practitioner can also notify the Indiana Animal Disease Diagnostic Laboratory or contact the Indiana Board of Animal Health.

To date, the definitive cause of the reported illnesses has not been deter-


mined; therefore, in suspect cases, the veterinarian should retain as much of the suspect pet food product as possible, as well as saving all ante-mortem or post-mortem samples from affected dogs. Any questions regarding sample collection and retention should be directed to the FDA, the Office of the Indiana State Chemist, or the Indiana Animal Disease Diagnostic Laboratory.

References:

1. Hooper AN and Roberts BK:2011. Fanconi Syndrome in Four Non-Basenji Dogs Exposed to Chicken Jerky Treats. JAAHA 47(6):e178-e186.
2. <http://www.fda.gov/AnimalVeterinary/NewsEvents/CVMUpdates/ucm280586htm>. (18 November 2011). FDA Continues to Caution Dog Owners About Chicken Jerky Products.

Congratulations to Huiling Wei, graduate student of Dr. Roman Pogranichniy, who won the American College of Veterinary Microbiologists award for her research and poster presentation at the recent Conference for Research Workers in Animal Disease, held in Chicago, IL.

Her project was titled "Development of DNA vaccine against H1N1 subtype swine influenza viruses" and was co-authored by Drs., Steven Lenz, D.H. Thomson and Roman Pogranichniy.



BVD in White-tailed Deer in Indiana

By Kay Hagen

Reprinted with permission from Purdue Veterinary Medicine

Research underway in Dr. Roman Pogranichniy's laboratory is linking a common cattle disease to white-tailed deer in Indiana. Bovine Viral Diarrhea Virus (BVDV) is an economically important disease that is estimated to cause between \$760 million and \$2.2 billion in losses each year for cattle producers in the United States. Both cattle producers and veterinarians have campaigned for the eradication of this disease.

"In order for a control program to be successful, the source of infection needs to be understood to prevent reintroduction to herds that are free of infection," says Dr. Pogranichniy, Associate Professor of Virology in the Department of Comparative Pathobiology and Head of Serology/Virology in the Animal Disease Diagnostic Laboratory.

He postulated that white-tailed deer could be a reservoir for the disease. So, in 2006, Dr. Pogranichniy, with cooperation from the Indiana Department of Natural Resources, began collecting samples from white-tailed deer harvested by hunters. Indiana hunters are required to "check in" their deer at DNR-approved stations, and these check-in stations provided an ideal place to gather ear notch samples from the deer for further testing.

"One sample from a lymph node, and one ear notch from two different white-tailed deer were BVDV positive," says Dr. Pogranichniy. From those samples he was able to determine that a small percentage of white-tailed deer in Indiana were infected with BVDV.

"White-tailed deer and cattle do share common pastures," says Dr. Pogranichniy. So the next step was to determine if deer could transmit the virus to cattle.

A subsequent study showed that calves can be infected with BVDV from white-tailed deer. Dr. Pogranichniy says this underscores the importance of taking wild animals into account when creating disease prevention protocols.

"BVDV from wild deer can be transmitted to calves through oral or nasal pathways. These animals co-mingle because they may share the same pasture," he says. These findings could be especially important to cattle producers with cows on pasture.

If a cow is infected with the virus during gestation, embryonic death, abortion and congenital defects can occur. Additionally, calves born to infected mothers may present with fever, discharge from the nose and eyes, profuse diarrhea and mucosal lesions.

But perhaps more importantly, says Dr. Pogranichniy, "Fetuses between 18 and 125 days of gestation that survive infection with BVDV invariably develop immune tolerance to the virus and are born persistently infected (PI). Persistently infected animals shed large amounts of virus during their lifetime and are the primary spreaders of the virus in the herd. Additionally, they do not respond to treatments for, or vaccinations against, BVDV. In ADDL, we established diagnostic assays to help veterinarians and producers diagnose BVD infection in cattle.

Dr. Pogranichniy is continuing his work with BVDV and is investigating management practices related to its prevention and control in Indiana.



MAST CELL TUMORS REVISITED

by Drs. Jose Ramos-Vara, Peg Miller, ADDL Pathologists, and Dr. Joshua Webster, National Cancer Institute

Mast cell tumors (MCTs) are one of the most common neoplasms in the skin of dogs, accounting for 7-21% of all cutaneous tumors. In the last few years, significant advances in the diagnosis and prognostication of MCTs have been made. This article reviews different aspects of canine MCT, with focus on its classification and the use of immunologic and molecular tools for prognostication.

Three-tier grading versus two-tier grading of cutaneous mast cell tumors. The current grading system of MCTs is based on a 3-tier grading scheme by Patnaik et al, which was designed for dermal mast cell tumors. According to this system, grade 1 MCTs are the least malignant, and more than 90% of dogs survive longer than 1500 days. Neoplastic cells are well-differentiated and confined to the dermis. Mitotic figures are not detected and stromal reaction or necrosis is minimal. Forty-seven percent of dogs with grade 2 (intermediate malignancy) survive longer than 1500 days. Grade 2 MCTs are more cellular than grade 1, have more irregular nuclei, finer cytoplasmic granules and extend into the subcutis. They have low to moderate mitotic index (0-2 mitotic figures/high power field [hpf]). Some contain areas of edema, necrosis or hemorrhage and stromal reaction. Grade 3 MCTs are the most malignant and are characterized by high cellularity, pleomorphic cells with indented to round vesicular nuclei and prominent nucleoli. Grade 3 MCTs typically have 3-6 mitotic figures/hpf and have areas of necrosis, hemorrhage and hyalinized collagen. Only 6% of dogs with grade 3 MCT survive longer than 1500 days. Due to the proven inconsistency among pathologists in grading MCTs based on this 3-tier system, its unsuitability for MCTs confined to the subcutis, and the ambiguity and questionable prognostic value of the intermediate-grade, a new 2-tier grading system has been developed and its clinical value is being evaluated. According to this 2-tier grading, a high-grade MCT is one that has any of the following features: at least 7 mitotic figures/10 hpf; at least 3 multinucleated (more than 2 nuclei) cells in 10 hpf; at least 3 bizarre nuclei in 10 hpf; at least 10% karyomegalic cells. Initial results published recently indicate that dogs with high-grade MCTs (using the 2-tier grading system) have significant shorter time to additional tumor development and/or metastasis as well as shorter survival times (less than 4 months for high-grade MCTs versus more than 2 years for low-grade MCTs). This two-tier grading system appears to be more consistently applied by veterinary pathologists than the 3-tier grading system, and at times will be used in the pathology report as a complement to the classic 3-tier (Patnaik) system.

Should I send a biopsy of the regional lymph node from a dog with MCT? In a recent study, about 28% of the low-grade (2-tier grading)/grade II (3-tier grading) cutaneous MCTs had metastasized to the regional lymph node. More importantly, none of the cytologic features distinguished low-grade tumors that metastasized from those that did not. The significance of this finding in terms of case outcome is not clear because follow-up information was not available. However, submission of the regional lymph node for histologic evaluation, along with the cutaneous biopsy specimen, should be considered.

Canine subcutaneous mast cell tumor (SMCT). Most canine MCTs originate in the dermis and eventually extend into the subcutis. These MCTs are termed cutaneous mast cell tumors (CMCTs). However, a proportion of MCTs are localized to the subcutis without a dermal component (SMCTs). The original 3-tier (Patnaik) grading system did not include SMCTs, though the grading scheme has been applied to SMCTs, assuming their behavior is similar to that of CMCTs. Several publications have identified diagnostic and prognostic differences among CMCTs (those originating from the dermis) and SMCTs (those originating from the subcutis). Based on these studies, it is apparent that most SMCTs have a favorable prognosis, which is supported by extended survival times and fewer recurrences and metastasis when compared with CMCTs. In the study by Thompson et al, SMCTs were classified by a) growth pattern (*circumscribed tumor*), a well demarcated MCT with expansile behavior; *combined*, well demarcated solitary nodules of mast cells separated from normal soft tissue by abundant fibrous stroma; *infiltrative tumors*, similar to combined MCTs but with a distinct infiltrative behavior, b) degree of cellular atypia (anisocytosis and anisokaryosis), c) presence of multinucleated cells, d) cytoplasmic granules, and e) mitotic index (MI), which is the number of mitotic figures per 10 hpf. Results of this study show that SMCTs are rarely fatal (<10% of dogs will die of MCT-associated disease), have very low metastatic rate (4%), and low local recurrence (8%) even in those cases with incomplete surgical excision. The estimated 6-month, 1-, 2- and 5-year survival probabilities are 95%, 93%, 92%, and 86% respectively. Decreased survival time of SMCTs is associated with MI (median survival time for tumors with MI > 4 is 140 days and 950 days for tumors with MI ≤ 4), an infiltrative growth pattern, and presence of multinucleated mast cells. In summary, if the pathology report states that the MCT is subcutaneous with low MI (≤ 4), the prognosis is likely to be favorable. As in CMCTs, complete surgical excision (surgical margins free of neoplastic cells) of SMCTs greatly reduces the local recurrence and in many instances adjuvant treatment is not necessary.

Cell proliferation in canine MCTs. Cell proliferation correlates with the outcome of canine MCTs. There are several ways to determine cell proliferation in a diagnostic setting.

1. **Mitotic index (MI).** This is the simplest method to indirectly determine the cell proliferation index. It is performed on conventionally stained (HE) microscopic slides. MI evaluation is done in the area of the tumor with highest mitotic activity. In general, MI correlates with tumor grade and median survival time (MST). In one study, dogs with Patnaik's grade 2 MCT and MI ≤ 5 had an MST of 70 months, whereas those with MI > 5 had an MST of 5 months. Dogs with Patnaik's grade 3 MCT and an MI ≤ 5 have an MST of more than 6 months, but less than 2 months for those with MI > 5. As mentioned in the previous paragraph, the MI cutoff for canine subcutaneous MCTs is slightly different.
2. **Ki67 proliferation index.** Ki67 is a nuclear protein that is expressed in all phases of the cell cycle but is not expressed in noncycling cells. The relative number of Ki67-positive cells (detected by immunohistochemical staining) in a tumor constitutes the proliferation index (growth fraction of the tumor). The number of Ki67-positive cells is associated with an increased risk of tumor recurrence at the original site or elsewhere, as well as an increased risk of MCT-related mortality.

KIT protein expression in canine MCTs. Several mammalian cells, including mast cells, have a tyrosine kinase KIT receptor, which is encoded by the *c-KIT* proto-oncogene. This oncogene is important in normal mast cell survival, proliferation, differentiation, and migration. There are 3 patterns of KIT expression in MCTs: Pattern I (cytoplasmic membrane); pattern II (focal to stipple cytoplasmic expression); pattern III (diffuse cytoplasmic). Several publications have confirmed that increased cytoplasmic expression of KIT protein (patterns II and III) is correlated with increased local recurrence and decreased survival time. Aberrant KIT protein localization (patterns II and III) is also associated with increased cellular proliferation and *c-KIT* mutations.

***c-KIT* mutations in canine MCTs.** These mutations are most commonly present in the juxtamembrane domain of the receptor KIT, mainly in exon 11 and less commonly in exons 8 and 9, and consist of internal tandem duplications and deletions. *c-KIT* mutations in canine MCTs are significantly associated with an increased risk of recurrence and death, and a higher tumor grade. Tyrosine kinase inhibitors are used in the treatment of some canine MCTs with *c-KIT* mutations.

Evaluation of canine MCTs at the Purdue Animal Disease Diagnostic Laboratory. The ADDL offers standard tumor grading of MCTs based on the current grading system, including determination of the mitotic index. When appropriate, we will also evaluate MCTs based on the proposed 2-tier grading system as part of the standard biopsy fee. In addition, we offer immunohistochemical evaluation of cell proliferation (Ki67 index) and KIT protein expression. Currently, the ADDL does not perform molecular tests for *c-KIT* mutations, but we can submit samples to a reference laboratory for that analysis. The main reason for this multi-faceted approach to diagnosis and characterization of various

Mast Cell Tumors Revisited, continued

morphologic, immunohistochemical and molecular aspects of canine MCTs is to refine and customize treatment. This approach is summarized in Fig. 1 which depicts a canine cutaneous MCT treatment algorithm followed by the Colorado State University Animal Cancer Center. Keep in mind that other schemes are available and large scale studies are still pending to support this or other approaches to MCT treatment. Our advice is to consult with your oncology service for treatment purposes.

How to be sure that the pathologist is looking at the actual surgical margins? This is one of the most critical points that a pathologist must address in the biopsy report. Regardless of the type of tumor, chances of recurrence are altered by complete (no neoplastic cells in the margins) versus incomplete (presence of neoplastic cells in surgical margins) excision. Tagging different sites of a mass with a suture is a common method to mark margins, but it does not mark the entire

surface of the margin (i.e., tagging to good to geographically place a particular area of a mass—cranial, lateral, medial, etc) and does not appear in histologic sections. Therefore, the preferred method is painting of surgical margins (<http://www.addl.purdue.edu/newsletters/2004/winter/tubiop.asp>). We prefer dark colors, such as black, blue and green to bright shades such as red, yellow or orange which may fade in histological processing or be difficult to observe under the microscope. Evaluation of painted margins requires extra technician time and additional sections, which translates into additional cost to the surgical biopsy fee. To paint surgical margins, first blot the surface to be painted, apply the dye, and let it air dry for about 10 minutes before placing it in formalin. Most margins in cutaneous biopsy specimens will be very fatty; to enhance the retention of the dye in adipose tissue, the use of a mordant (e.g., acetic acid) sprayed on the tissue surface before applying the dye is recommended.

References are available on our website <www.addl.purdue.edu>

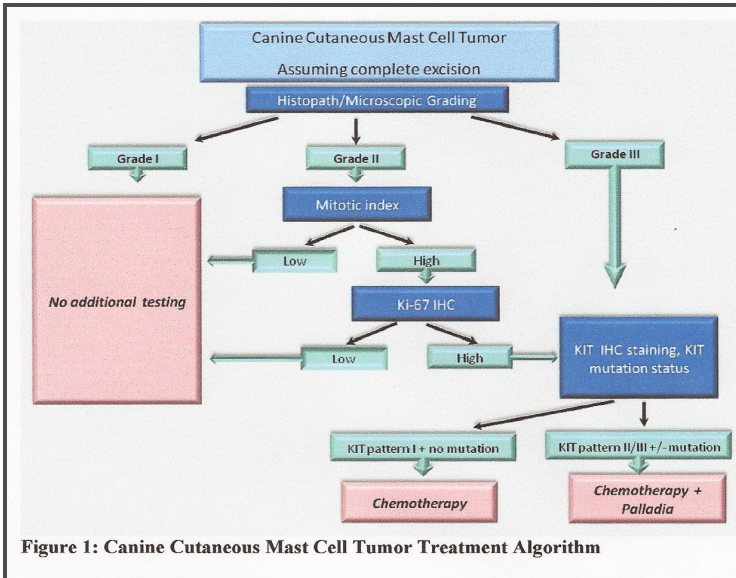


Figure 1: Canine Cutaneous Mast Cell Tumor Treatment Algorithm

<http://www.dlab.colostate.edu/webdocs/services/MCYPProfileInformation.pdf>
 Reprinted with permission from Colorado State University, Molecular Pathology Laboratory—
 Animal Cancer Center

Purdue ADDL and Heeke ADDL will be closed on the following University holidays in 2012.

January 16.....	Martin Luther King Day
May 28.....	Memorial Day
July 4.....	Independence Day
September 3.....	Labor Day
November 22-23.....	Thanksgiving
December 24-25.....	Christmas

Non-Profit Organization
 U.S. Postage PAID
 PURDUE UNIVERSITY

ANIMAL DISEASE DIAGNOSTIC LABORATORY
 406 S. UNIVERSITY
 WEST LAFAYETTE, IN 47907